

# 27

# Restoration of the Periodontally Compromised Dentition

*Arnold S. Weisgold and Neil L. Starr*

## **NATURAL DENTITION**

### **IMPACT OF ESTHETICS**

### **PERIODONTAL BIOTYPES**

### **ROLE OF OCCLUSION**

### **TREATMENT PLANNING AND TREATMENT SEQUENCING WITH AND WITHOUT ENDOSSEOUS IMPLANTS: A COMPREHENSIVE THERAPEUTIC APPROACH TO THE PARTIALLY EDENTULOUS PATIENT**

Diagnostic Evaluation  
Esthetic Treatment Approach

## **DENTAL THERAPEUTICS: WITHOUT IMPLANTS**

### **DENTAL THERAPEUTICS: WITH IMPLANTS**

Outcome-Based Planning  
Considerations at the Surgical Phase  
Transitional Implant-Assisted Restoration  
Final Prosthetic Phase of Treatment  
Long-Term Maintenance/Professional Care

## **CONCLUSION**

---

Portions of this chapter are from Starr NL: Treatment planning and treatment sequencing with and without endosseous implants: a comprehensive therapeutic approach to the partially edentulous patient, *Seattle Study Club Journal* 1:1, 21-34, 1995.

The term *periodontal prosthesis*<sup>1,2</sup> was coined by Amsterdam about 50 years ago. He defined periodontal prostheses as “those restorative and prosthetic endeavors that are absolutely essential in the treatment of advanced periodontal disease.” New, more sophisticated techniques are currently available, and with the advent of endosseous implants<sup>3</sup> many patients can avoid wearing a removable prosthesis, or at least have one that is extremely stable. Nevertheless, the concepts of identifying the etiologic risk factors, establishing an accurate diagnosis and prognosis, formulating an interdisciplinary treatment plan, and developing a logical sequence of therapy hold as true today as they did five decades ago. In this new millennium, the philosophy of periodontal prosthesis has gained universal acceptance as the foundation of interdisciplinary dental therapeutics.

### NATURAL DENTITION

The major goal of the dentist is the preservation and maintenance of the natural dentition in a state of health. With increased use of the endosseous implant, it appears at times that some in the profession have lost sight of this *major* responsibility. In the past, teeth with a poor or guarded prognosis were frequently maintained, whereas today there is an option to extract them and replace them with dental implants. The concern, however, is knowing when to save or extract a tooth. In light of the observations of many astute clinicians, developing a treatment plan that will provide the best long-term prognosis is a challenge in the advanced periodontally involved dentition. If anything has been learned from the retention of these severely compromised teeth, it has been the healing potential of the periodontium once the known etiologic risk factors are eliminated or controlled.<sup>4</sup>

### IMPACT OF ESTHETICS

Esthetics and osseointegration were developing on parallel paths during the mid-1980s to early 1990s and have emphasized the importance of the integrated team approach to achieve the ultimate periodontal and restorative result. Maintaining the papilla between two teeth is somewhat predictable,<sup>5</sup> but between a tooth and an adjacent implant is less predictable.<sup>6,7</sup> Concern for the loss of or reduction in height of the papilla between two adjacent implants has created a new esthetic concern.<sup>8</sup> Therefore, the concepts of selective extraction of teeth, socket preservation, and augmentation at the time of tooth extraction appear to be invaluable in the restoration of form, function, and esthetics<sup>9-14</sup> (see Chapter 26).

Esthetics play a major role in our diagnostic and therapeutic endeavors. However, long-term clinical assessments have shown that its real value will play out optimally

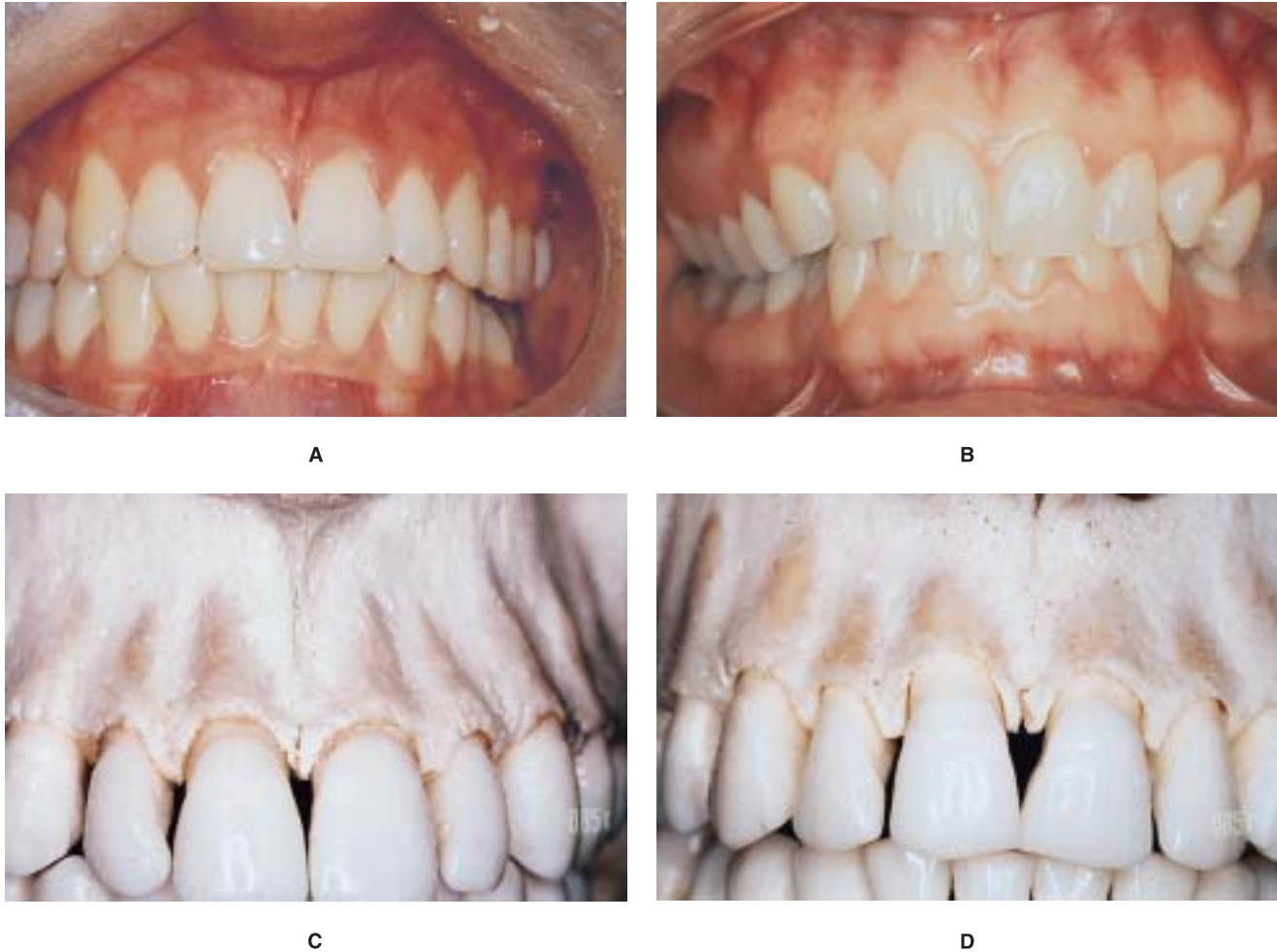when it is achieved in concert with all the functional needs of the dentition.

### PERIODONTAL BIOTYPES

Ochsenbein and Ross,<sup>15</sup> Weisgold,<sup>16</sup> and Olsson and Lindhe<sup>17</sup> suggested two distinct types of periodontium found in humans. Becker and colleagues<sup>18</sup> reported that there are three periodontal biotypes: flat, scalloped, and pronounced scalloped. Measuring from the height of the bone interproximally to the height at the direct midfacial, their findings were as follows: flat = 2.1 mm; scalloped = 2.8 mm; and pronounced scalloped = 4.1 mm. *Note that the distance in the pronounced scalloped is approximately twice as great as in the flat type.* Normally, the distance from the cemento-enamel junction (CEJ) to the crest of bone on the direct facial in a healthy periodontium of a young adult is approximately 2 mm, with the gingival margin being located on the enamel (slightly coronal to the CEJ). However, in the pronounced scalloped type, the distance between CEJ and the bone on the direct facial is usually 3 to 4 mm. This results in the gingival margin being located at the CEJ, or quite often, on the cementum—that is, in the pronounced scalloped type, the gingival margin is, in a sense, located on the root in health. This type of periodontium, because of its thinness and friability, is more likely to recede than the flat type. There is no question that the most favorable gingival and esthetic results occur in the flat type, not the pronounced scalloped type (Fig. 27-1; Boxes 27-1 and 27-2).

Tarnow and colleagues<sup>5</sup> observed that in healthy mouths the gingival papilla filled the space between teeth 100% of the time when the distance from the contact point of adjacent teeth to the interproximal crest of bone was 5 mm or less. When the distance was 6 mm, the papilla did not fill the space completely in approximately 50% of the patients, and when it was 7 mm or more, it did not fill the space in about 75% of the cases. The pronounced scalloped periodontal biotype (because of its triangular-shaped tooth) usually has a distance between 6 and 7 mm. Hence, under normal conditions, this is the tissue type that usually has some interproximal recession with the formation of “black triangles”. Further clinical insults to soft tissue, such as tooth preparation, excessively rapid orthodontic tooth movement, tooth extraction, scaling and root planing, and injudicious retraction of soft tissue may increase the gingival recession, thus further compromising the esthetic result (Fig. 27-2).

The extraction of an anterior tooth usually results in resorption of bone on the facial and interproximal surface (Fig. 27-3). In addition, a decrease in the faciolingual dimension of the interproximal areas is not uncommon. These findings are more obvious in the scalloped type of periodontium, and even more so, in the pronounced



**Figure 27-1.** A, Thin-scalloped periodontal biotype. B, Thick-flat periodontal biotype. C, Thick-flat skull material. D, Thin-scalloped skull material. (Courtesy Dr. Clifford Ochsenbein, Dallas, Tx.)

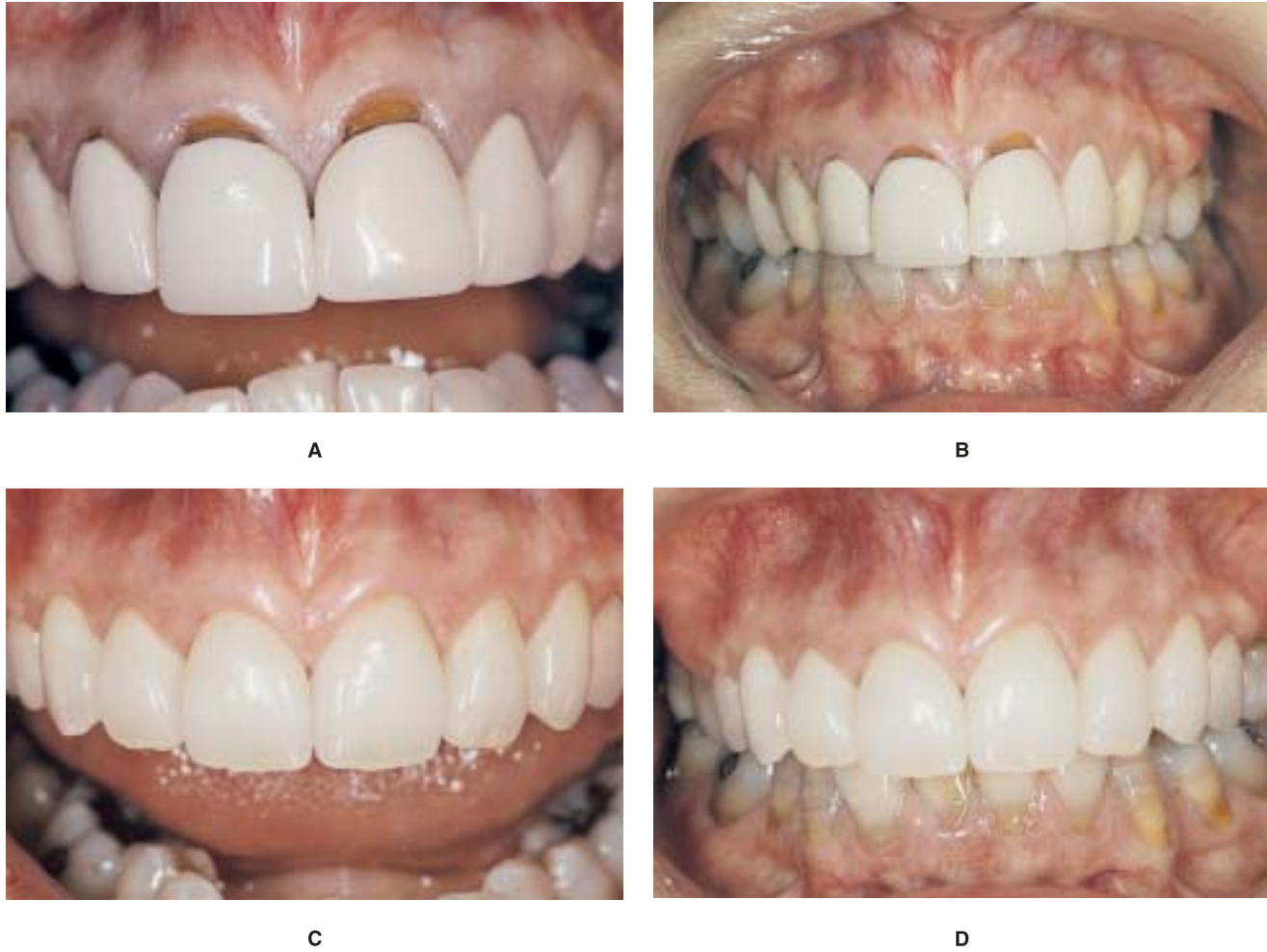**Box 27-1** Description of Thin/Scalloped Periodontal Biotype

- Distinct disparity between height of gingival margin on direct facial and that interproximally
- Delicate and friable soft tissue curtain
- Underlying osseous form scalloped, dehiscences and fenestrations often present
- Small amount of attached masticatory mucosa (quantitative and qualitative)
- Reacts to insult by recession
- Subtle, diminutive convexities in cervical thirds of facial surfaces
- Contact areas of adjacent teeth located decidedly toward the incisal or occlusal thirds
- Teeth “triangular” in shape
- Contact areas of adjacent teeth small faciolingually and incisogingivally
- Steeper posterior cusps

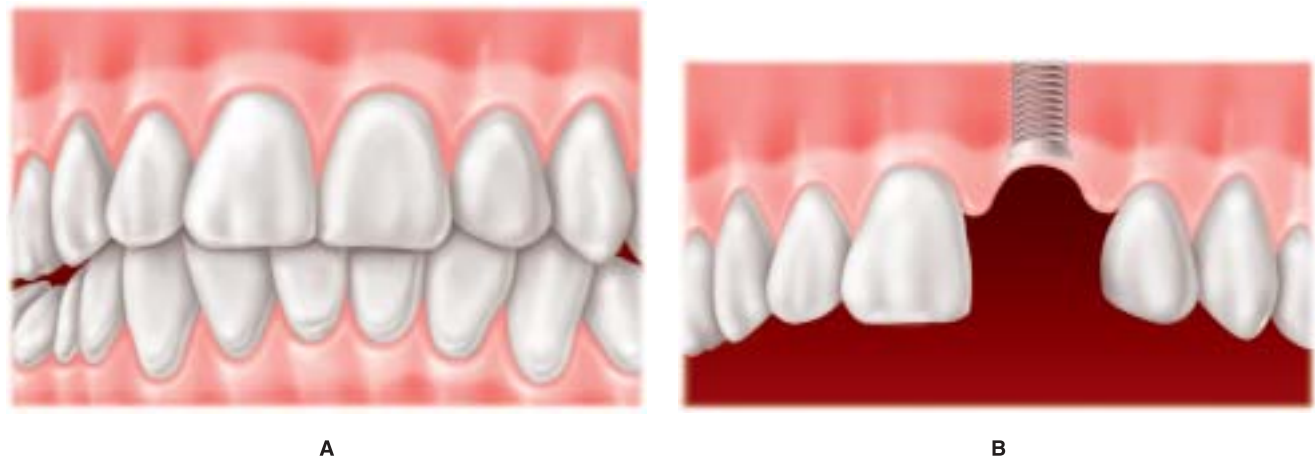
**Box 27-2** Description of Thick/Flat Periodontal Biotype

- Not as great a disparity between height of gingival margin on direct facial and that interproximally
- Denser, more fibrotic soft tissue curtain
- Underlying osseous form flatter and thicker
- Larger amount of attached masticatory mucosa (quantitative and qualitative)
- Reacts to insult by increased pocket depth
- More prominent, bulbous convexities in cervical thirds of facial surfaces
- Contact areas of adjacent teeth located more toward the apical
- Teeth “square” in shape
- Contact areas of adjacent teeth larger faciolingually and incisogingivally
- Flatter posterior cusps



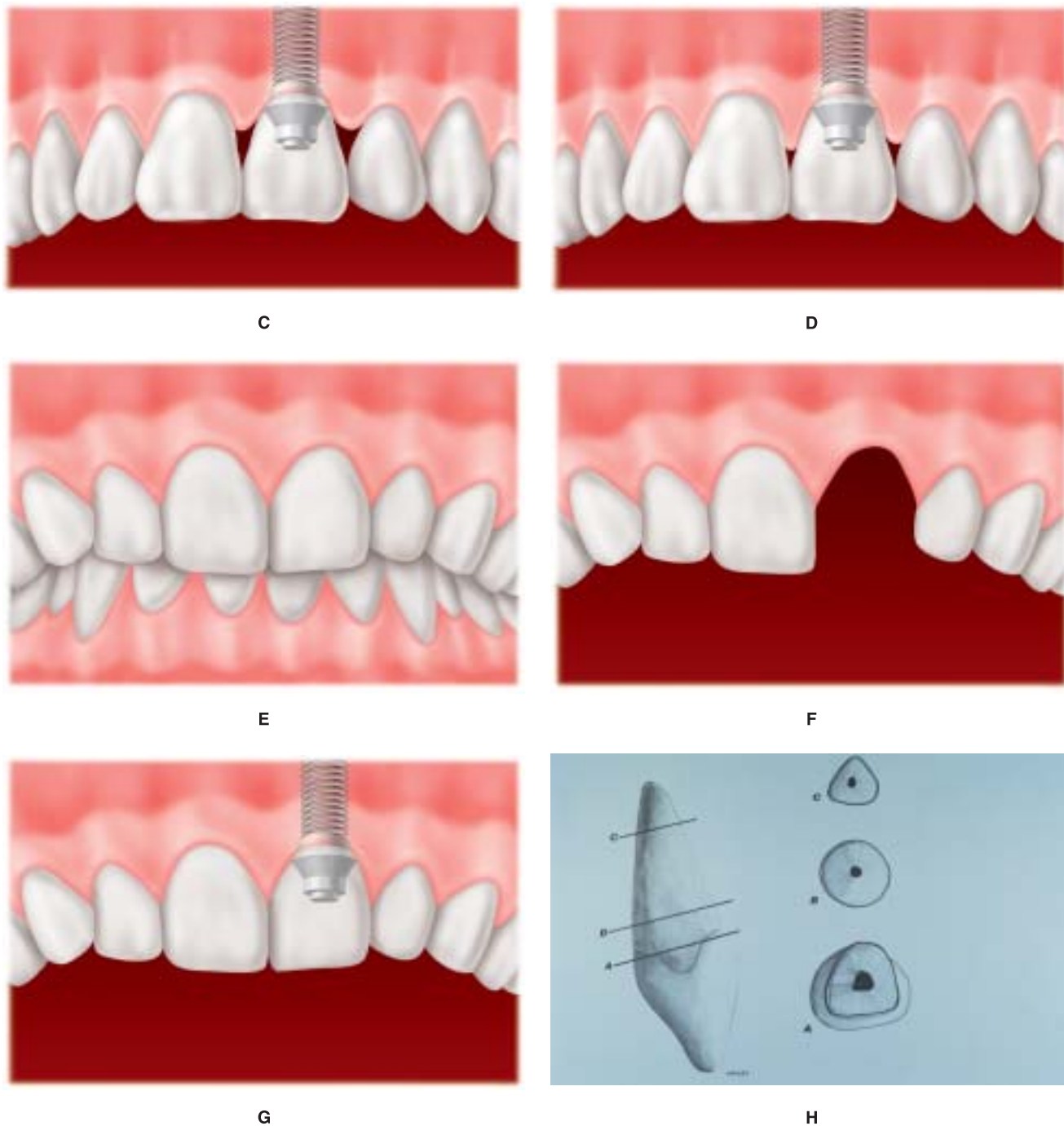


**Figure 27-2.** A and B, Maxillary anterior teeth with facial margins of crowns exposed and failing composite restorations. C and D, All ceramic crowns for maxillary anterior teeth, respecting the gingiva and harmonizing with the gingival topography.



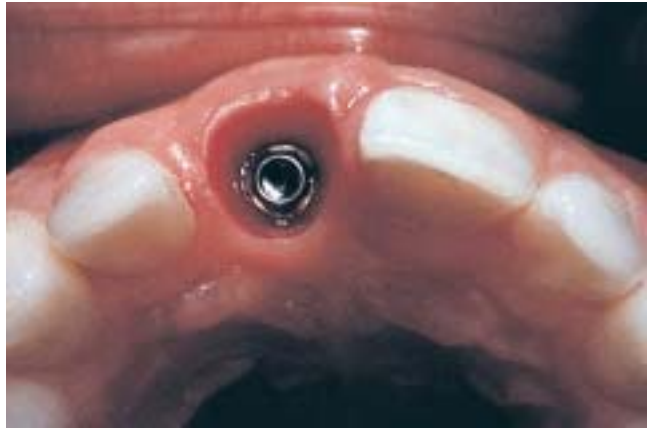**Figure 27-3.** A, Preoperative view before extraction of maxillary left central incisor. B, Placement of implant at 2 months after extraction. Note the recession of the interproximal papillae.

*Continued*

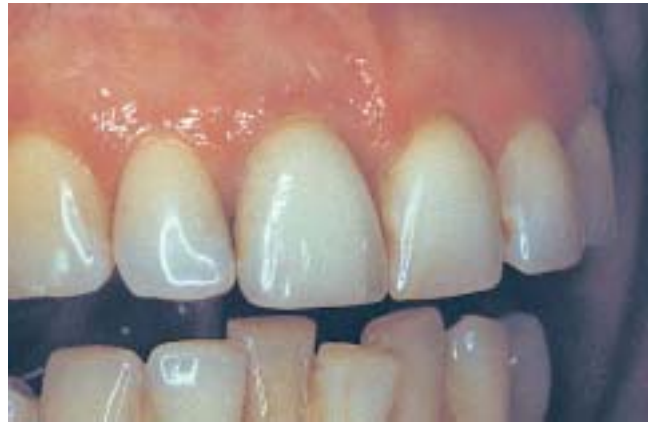

**Figure 27-3. cont'd** C, Insertion of final crown (“black” triangles). D, Addition of porcelain on mesial and distal—results in masking the dark areas, but also a wider crown. E, Preoperative view before extraction of maxillary left central incisor. F, Two months after extraction. Note there is little to no papillary recession. G, Placement of final crown. Note that esthetic result compares favorably to preextraction (E). H, Diagram illustrating the cross-sectional forms of a maxillary central incisor. Note it is triangular at the cemento-enamel junction.

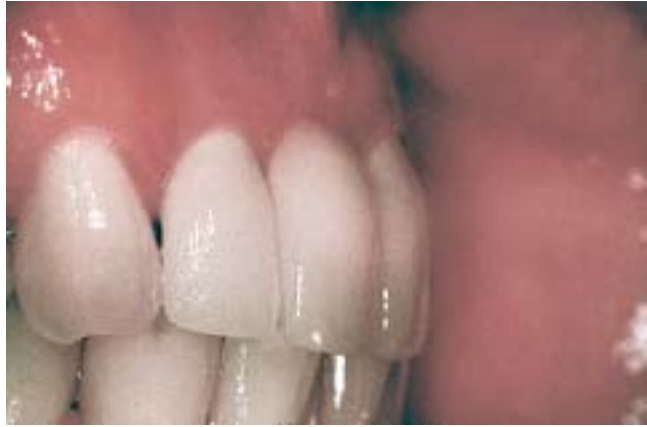*Continued*



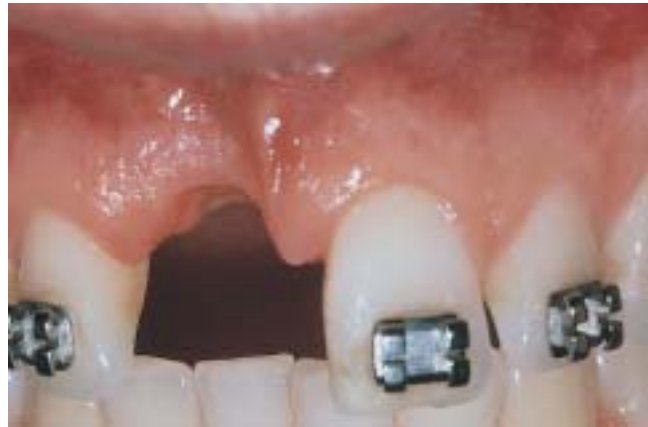I



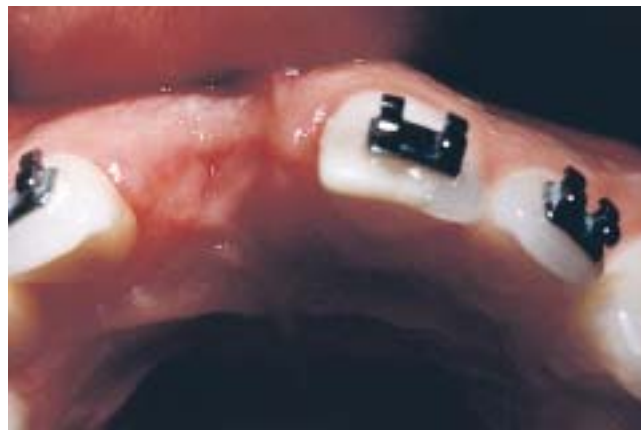J



K



L



M

**Figure 27-3. cont'd** I, The ideal sulcus/implant relation. This situation is usually not commonly found because most often the facial plate of bone and interproximal areas resorb somewhat. J, Maxillary right central incisor. The ideal artificial crown/implant/periodontal relationship. K, Maxillary right central incisor. Note there are ceramo-metal crowns on the right lateral incisor and left central incisor natural tooth. The right central incisor crown is on an implant. Note the slight "ridge lap" in cervical because ridge is slightly resorbed on the facial surface and out of necessity the implant is placed toward the palatal area. L, Facial view showing resorbed ridge in maxillary right central incisor area. Note vertical deficiency. M, Incisal view of the same area. Note deficiency faciopally.

scalloped type. This may create an esthetic dilemma for both the patient and the dentist. Complicating the matter is that the morphology of the roots of the anterior teeth is usually more tapered, both faciolingually and mesiodistally than those found in the flat type periodontium. The end result of extracting an anterior tooth with a scalloped type periodontium is: (1) Greater loss of interproximal hard and soft tissues; (2) the interproximal papillae are positioned more palatally; and (3) a wider mesiodistal dimension between the adjacent teeth (because of the taper of their roots). The outcome is a large noticeable “black triangle,” which is often treated by closing the space with a wider crown or laminate<sup>19</sup> placed on the adjacent teeth, or the use of pink porcelain to simulate the lost gingiva. Often these options are not satisfactory.

### ROLE OF OCCLUSION

Success in occlusal therapy depends on controlling the etiologic factors that cause the problem (see Chapter 29). Unfortunately, occlusal disorders, at times, originate from a host of seemingly disparate, random factors. This led us to rely often on inadequate data and unproven techniques. Compounding the problem is the tendency to “mix vocabularies”—that is, giving different definitions for the same thing—and to commonly use different terminology (e.g., centric relation, centric occlusal relation, maximum intercuspal position, retruded contact position, and so on).

Occlusal trauma is injury to the attachment apparatus resulting from tooth-to-tooth contact, oral musculature activities, or foreign object to tooth contacts. *It is the failure of the supporting structure to resist or to adapt to these forces.*<sup>20</sup> Clinically, the most common finding is tooth mobility, and, radiographically, widened periodontal ligament spaces of the involved teeth are often seen.

**Primary occlusal trauma** can occur in a healthy mouth or one affected by periodontal disease. It is caused by forces greater than those that occur during normal function. It is usually caused by a parafunctional habit (i.e., bruxism, clenching, and other habits).<sup>1,2,21</sup> It is thought that mastication is not a source of primary trauma because of the minimal amount of time devoted to this activity, subsequently minimizing tooth contact, and the buffering capability of the periodontal ligament. Removal or controlling of the forces should result in the reversal of the effects of primary traumatism.

**Secondary occlusal trauma** is usually associated with a periodontally compromised dentition that has resulted in severe bone loss and teeth with adverse crown-to-root ratios. Usually, the teeth are very mobile; therefore, the teeth are subjected to continued injury with normal forces such as mastication or deglutition, or both. It is

here where periodontal prosthesis is usually indicated. The splinting of teeth with partial or full coverage crowns is indicated in most cases.<sup>1,2,22</sup> Successful management of periodontal disease and occlusal trauma is the goal of periodontal prosthetics.

**Posterior bite collapse** is the result of the loss of one or more posterior teeth, with drifting of adjacent teeth, extrusion of opposing teeth, and the creation of uneven marginal ridge relations and adjacent CEJ levels, and concomitant unlevelled bony crests. These events establish an environment where the self-protective capacity of the teeth is compromised; resulting in the development of angular bony crests frequently predisposing to infrabony pocket formation and posterior interproximal caries. The occlusal vertical dimension is supported by the posterior occlusion but with posterior tooth loss, the forces of occlusion are on the remaining anterior teeth. In addition, the remaining anterior teeth must provide anterior guidance, disarticulating the posterior teeth through excursive movements of the mandible. This will have a significant impact on their long-term function and viability.<sup>23</sup>

When posterior bite collapse has occurred, the restoration of form and function is more difficult to accomplish. Posterior occlusion must be reestablished, the occlusal vertical dimension restored and the anterior incisal guidance developed in concert with the posterior cusp height. This should allow for disarticulation of the posterior teeth during excursive movements of the mandible.

Given the abundance of research data and good clinical documentation,<sup>24-33</sup> important questions relative to occlusal etiology and the effects that trauma has on the progression of existing periodontal disease may be answered. Ultimately, this will establish a more “outcome-based” approach to occlusal therapy. For example, when the patient is periodontally susceptible and the posterior teeth in the same arch are seriously compromised or missing, the remaining anterior teeth may be stressed unfavorably, demonstrating varying degrees of mobility.<sup>23</sup> Placing posterior implants with fixed/splinted crown and bridgework is the preferred treatment for this patient type.<sup>23</sup> The restoration of the posterior occlusion at the correct occlusal vertical dimension can significantly decrease or eliminate the mobility patterns present in the anterior teeth and thereby help to stabilize them.

One must not downplay the role of occlusion evidenced by the manifestation of occlusal trauma on the endosseous implant prosthesis and its component parts. This is often a more common observance than damage to the surrounding bone or the implant. Without the cushioning effect of the periodontal ligament, the forces have a greater potential to cause breakage of the prosthetic parts, or of the implant to bone contact itself.<sup>34</sup>



### TREATMENT PLANNING AND TREATMENT SEQUENCING WITH AND WITHOUT ENDOSSEOUS IMPLANTS: A COMPREHENSIVE THERAPEUTIC APPROACH TO THE PARTIALLY EDENTULOUS PATIENT

The ultimate therapeutic goal is to achieve maximum health, masticatory function, speech, aesthetics, and comfort for the patients.<sup>35</sup>

The treatment can be divided into three levels:

1. Emergency care for relief of pain or sudden dysfunction
2. Removal of the causative factors of the disease processes
3. Removal of the consequences of the disease or traumatic insult

Level one, emergency treatment, must be accomplished before any other level of therapy is instituted (Table 27-1).

The purpose of the second level is to control infection. A basic tenet of periodontal therapy is the debridement of all accretions adherent to the clinical crowns and roots of teeth or restorative materials, both supragingivally and subgingivally. This is accomplished by scaling and root planing procedures in concert with oral hygiene instruction. If dental caries is present, the early placement of “direct-filling” restorations prevents the need for more extensive intervention later. In addition, the control of adverse occlusal forces should be managed at this level.

The third level of care is the focus of this chapter: attempting to correct alterations in form and function because of the effects of periodontal infections and traumatic injury to the teeth and their supporting tissues.

#### Diagnostic Evaluation

Diagnosis, treatment planning, and treatment sequencing continue to be significant challenges for the general dentist and specialist in the management of the partially edentulous patient. A comprehensive dental/periodontal examination must first be performed. This will ensure that all members of the treating team have addressed

each problem area and have collated their respective treatments into the overall therapeutic program.

The clinical evaluation consists of caries, periodontal, endodontic, orthodontic, orthognathic, occlusal and temporomandibular joint exams, as well as a comprehensive physical evaluation or medical history (Box 27-3). To facilitate this diagnostic evaluation, a full-mouth series of periapical radiographs of teeth and residual ridges must be obtained. A panoramic radiograph, a cephalometric radiograph, and a dental computed axial tomography (CAT) scan<sup>36</sup> are suggested if there is a need to help assess the bone quality and quantity, and supplement conventional dental radiography.

Impressions should be taken and models correctly articulated. In most situations, it is suggested that two sets of the original casts be obtained—one to be kept as a permanent record and the other to be used as part of the treatment planning. After gathering the necessary data, the information must be collated into a comprehensive treatment program.

Amsterdam<sup>1,2</sup> has stated that although the situation truly requiring periodontal prosthesis traditionally has been one of advanced dental disease, it became apparent that with certain modifications, its philosophy, concepts, principles, and techniques could be applied to any therapeutic endeavor involving the natural dentition.

#### Esthetic Treatment Approach

When a patient’s needs are primarily restoratively focused, such as veneering or crowning one or more teeth (Fig. 27-4), gingival aesthetic guidelines (Fig. 27-5) will be a significant component of the overall effort. In order to properly address the esthetic requirements of the patient, it is necessary to envision the desired outcome before performing the procedure.<sup>37</sup>

Esthetics is fundamentally about tooth form, and it is therefore most predictably realized with the assistance of an intraoral diagnostic “mock-up” to improve incisal form, lip line esthetics, and gingival topography (Fig. 27-6). The outcome is the development of an intraoral esthetic

TABLE 27-1 Emergency Treatments

PROBLEM	TREATMENT CATEGORY	TREATMENT
<ul style="list-style-type: none"> <li>• Deep/extensive caries</li> <li>• Occlusal trauma or myofascial pain syndrome</li> <li>• Large circumscribing periodontal/periapical lesions</li> <li>• Broken appliances</li> </ul>	<ul style="list-style-type: none"> <li>• Sedative restorations</li> <li>• Occlusal therapy</li> <li>• Extraction of hopeless teeth</li> <li>• Prosthetic repair</li> </ul>	<ul style="list-style-type: none"> <li>• “Direct-filling” or temporary crowns</li> <li>• Selective adjustment, appliance therapy, antiinflammatory medication</li> <li>• Interim fixed or removable restoration as necessary</li> <li>• Reestablish masticatory function and esthetics</li> </ul>



**Box 27-3** Diagnosis**Caries**

- Supragingival
- Subgingival
- Insufficient clinical crown height

**Endodontic Considerations**

- Symptomatic teeth
- Separated endodontic instruments
- Dystrophic calcifications
- Fractured roots
- Apical and lateral zones of osseous rarefaction
- Status of existing posts/cores

**Esthetics**

- Smile analysis
- Lip line analysis
- Gingival topography assessment
- Incisal plane assessment

**Malocclusion**

- Loss of occlusal vertical dimension

**Missing teeth**

- Without replacement
- With delayed replacement

**Occlusal Trauma**

- Primary
  - Bruxism
  - Clenching
  - Retrograde wear

- Secondary
- Temporomandibular joint considerations

**Orthodontics**

- Tooth drifting or bite collapse

**Periodontal Disease<sup>107</sup>**

- Degree of bone loss
- Topography of alveolar defect (potential impact of bone loss on adjacent teeth)
- Classification of periodontal biotypes

**Size and Shape of Residual Deformed Bony Ridge Areas**

- The degree of resorption will influence the surgical and restorative ventures

**Medical Status**

- Systemic disorders
- Psychologic concerns

**Traumatic Injury**

- Clinical crown deformity
- Soft and hard tissue deformities
- Facial deformity

**Developmental/Acquired Deformities**

- Cleft palate, cleft lip
- Amelogenesis imperfecta, other deformities

blueprint. This results in dentist verification, improved laboratory communication, and patient affirmation. Molds of the improved intraoral anatomic form of the teeth should be poured in stone, and then enhanced further in the dental laboratory with the application of wax. Silicone impressions are fabricated by the laboratory and then returned to the clinician to be used to verify proper tooth reduction.<sup>37</sup>

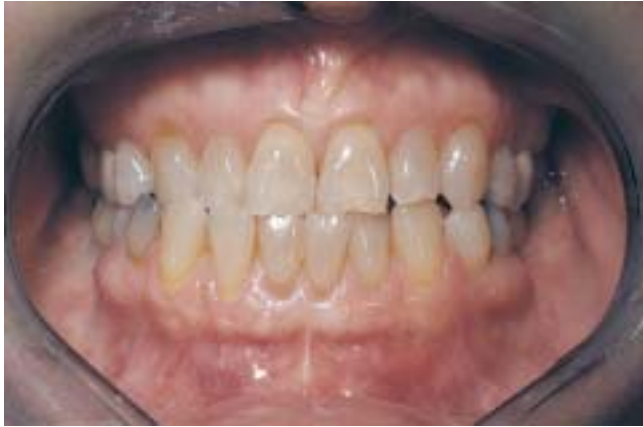The incorporation of one single-tooth implant and crown, together with a series of all ceramic crowns or veneers for the adjacent natural teeth, creates a great challenge for the clinician and dental ceramist.<sup>9</sup> Endosseous implant installation requires careful staging, in accordance with the healing time frames associated with tissue maturation. The addition of bone and soft tissue at or after tooth extraction, or tooth lengthening by restorative and/or surgical measures to achieve esthetic outcomes, requires even greater interdisciplinary planning (Box 27-4).

**DENTAL THERAPEUTICS: WITHOUT IMPLANTS**

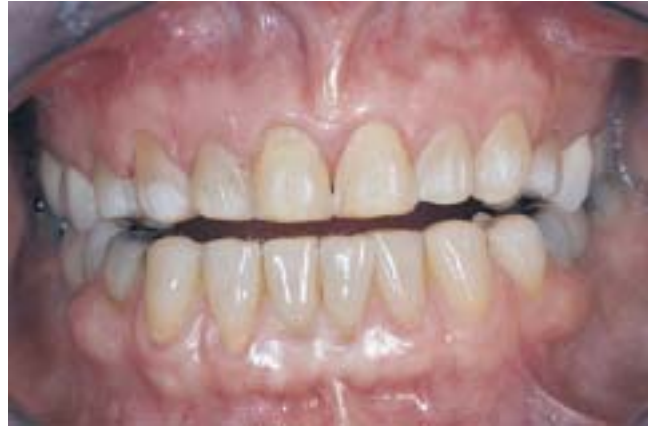Amsterdam<sup>1,2</sup> has stated that “the correction or modification of the deformities created by the disease may be much more complicated in therapy than the treatment of the active disease process.”

To establish a diagnosis in more compromised situations, it is important to ascertain the patient’s history of tooth loss. A host of etiologic factors may have contributed to tooth loss, such as caries, subsequent endodontic complications, traumatic injuries to teeth (and/or alveolus), periodontal disease, occlusal trauma, and iatrogenic dentistry.

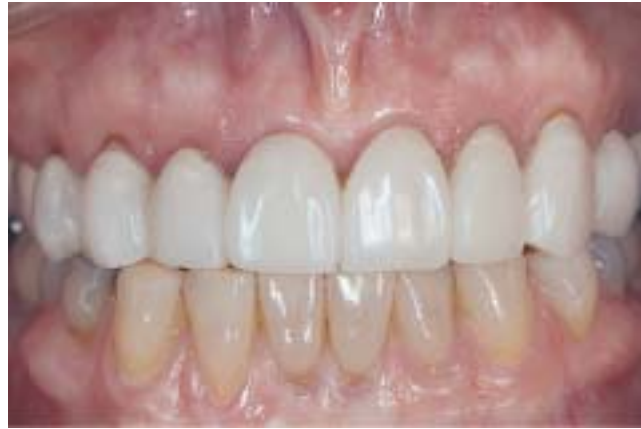Many teeth may serve as strong viable abutments. However, teeth substantially affected by periodontal disease, caries, or endodontic problems must be identified early because they may have minimal value as abutments for either individual crowns or splinted restorations. These



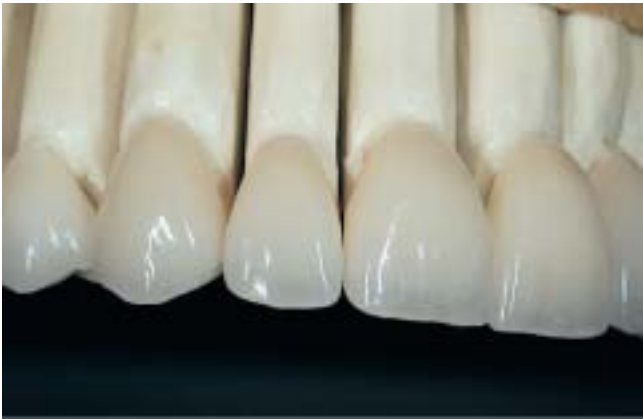A



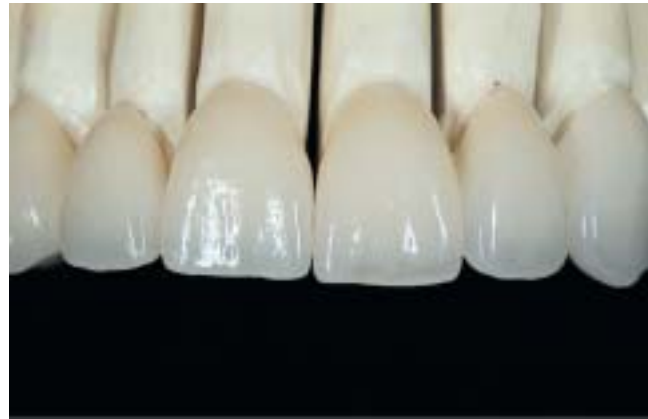B



C



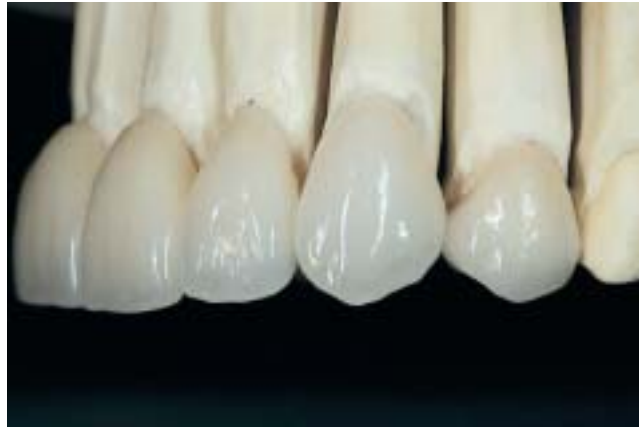D



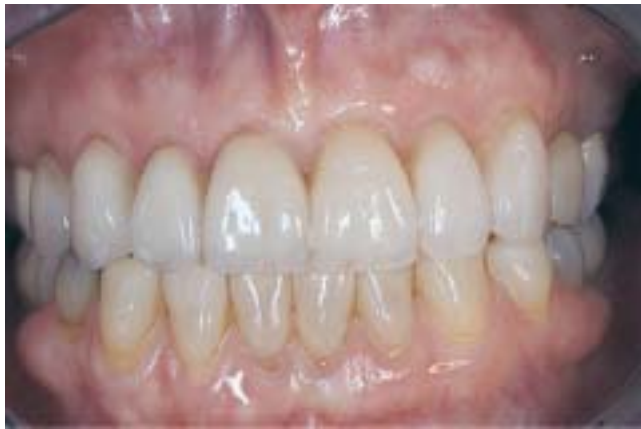E

**Figure 27-4.** **A**, Edge-to-edge maxillary incisor relation with crossbite at teeth #26, #27, and #28, demonstrating marked incisal wear. The dentoskeletal Class III arrangement (with thin lip form) exaggerates the flat facial profile. **B**, After performing a diagnostic composite mock-up, directed at creating anterior guidance, building out the teeth to enhance the facial profile, and improving the incisal edge relation to the lower lip, the maxillary teeth were prepared to receive ceramic veneers. The incisal edges of the mandibular teeth were reshaped by odontoplasty to create the proper overbite–overjet relation. **C**, Interim provisional acrylic veneer restorations. **D-F**, All ceramic veneers are on master stone model.

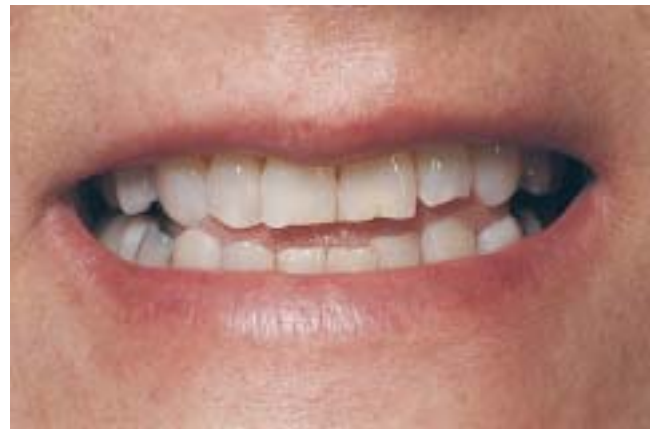*Continued*



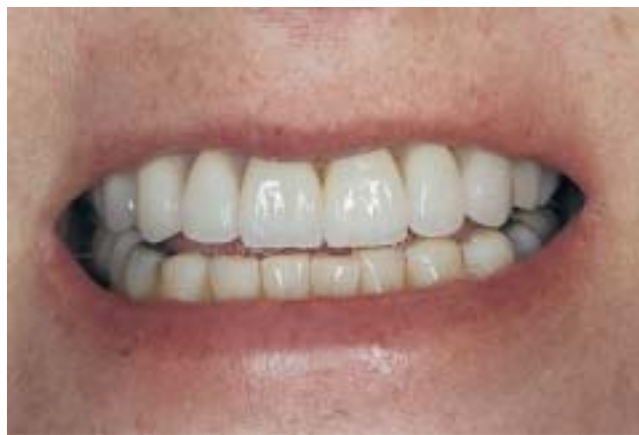F



G

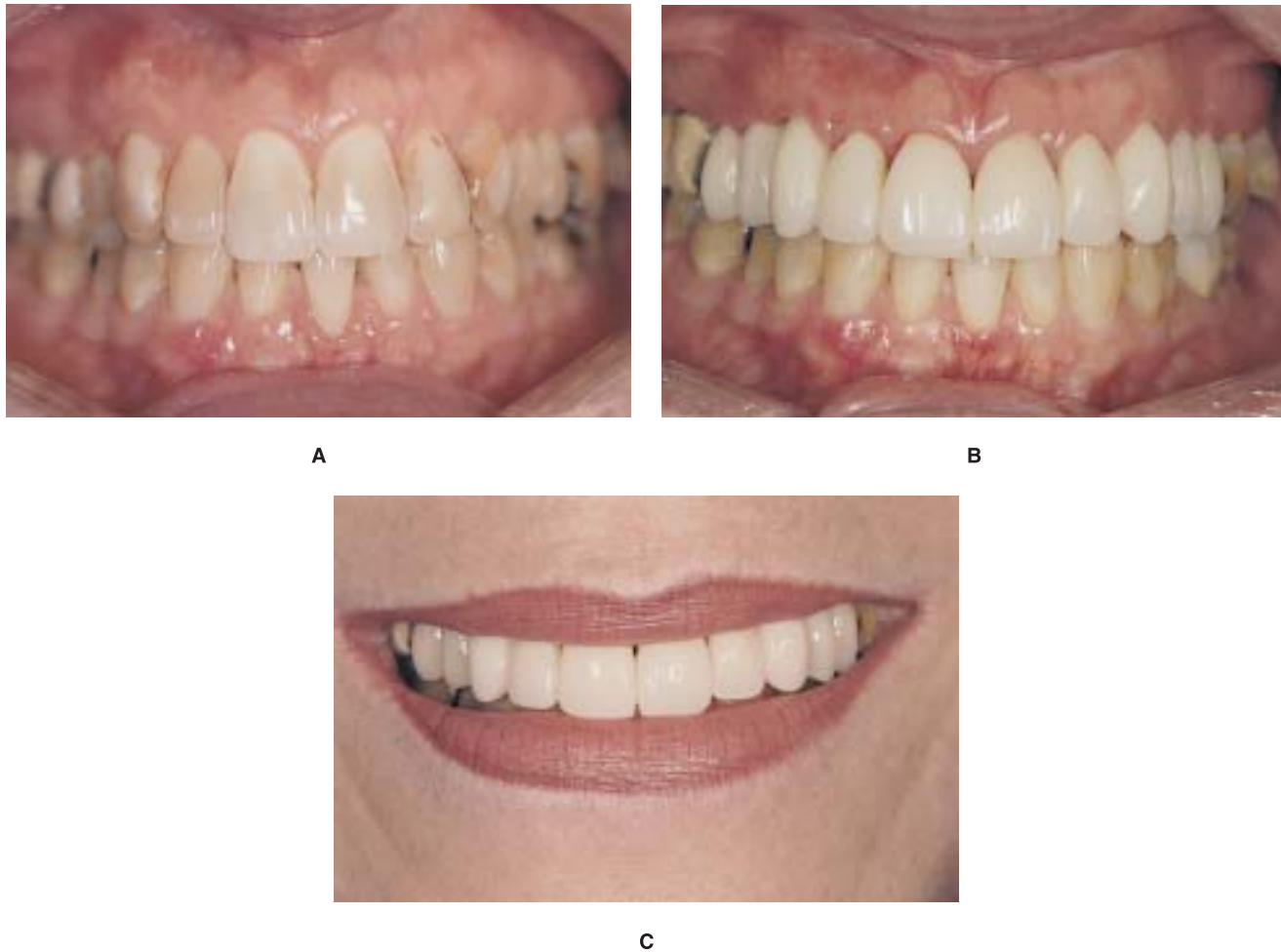

H



I

**Figure 27-4. cont'd** G, Final ceramic veneers for the maxillary teeth, with restored occlusal function and improved dental esthetics and facial aesthetics. H, Preoperative smile profile. I, Final ceramic veneers with smile profile.



**Figure 27-5.** **A**, Mottled enamel with marked discoloration and recurrent caries. **B**, Provisional acrylic restorations to restore form, function, and esthetics for the involved maxillary teeth. **C**, Smile photograph of the provisional acrylic restorations, creating both gingival and incisal balance with patient's lips and facial form.

teeth also may represent a serious periodontal liability to adjacent teeth.

When sophisticated dental therapy can be managed without the use of endosseous implants, the approach to treatment can be subdivided into periodontal, orthodontic/orthognathic surgery, occlusal, and restorative phases. These phases are interdependent, even if one may initially have precedence over another, or if two or more of the phases are initiated concurrently (Box 27-5).

The objective of periodontal therapy is directed toward eliminating the inflammatory process and establishing bone and soft tissue healing. Amsterdam<sup>1,2</sup> has noted that this is most predictably accomplished for teeth of normal anatomic root lengths with probing depths not exceeding 4 to 7 mm as measured from the CEJ (Fig. 27-7). The added advantage with this osseous surgical approach has been to increase the clinical crown length, thereby pro-

viding a final crown design with sufficient biomechanical retention/resistance.

When teeth require subgingival preparation to be treated with full coverage restorations, it is important to evaluate the mucogingival environment and determine the value of re-creating or enhancing the gingival tissues. Autogenous gingival grafts, subepithelial connective tissue grafts, and repositioning of an existing gingival complex are procedures commonly used.

The orthodontic phase strives to improve tooth alignment, to erupt fractured or impacted teeth, or to facilitate the extrusion of teeth with infrabony defects.<sup>38</sup> With these cases, it is prudent to consider a mucogingival procedure before tooth movement if a minimal zone of attached gingiva exists on the facial or lingual surface. This eliminates the concern regarding recession during orthodontic treatment.



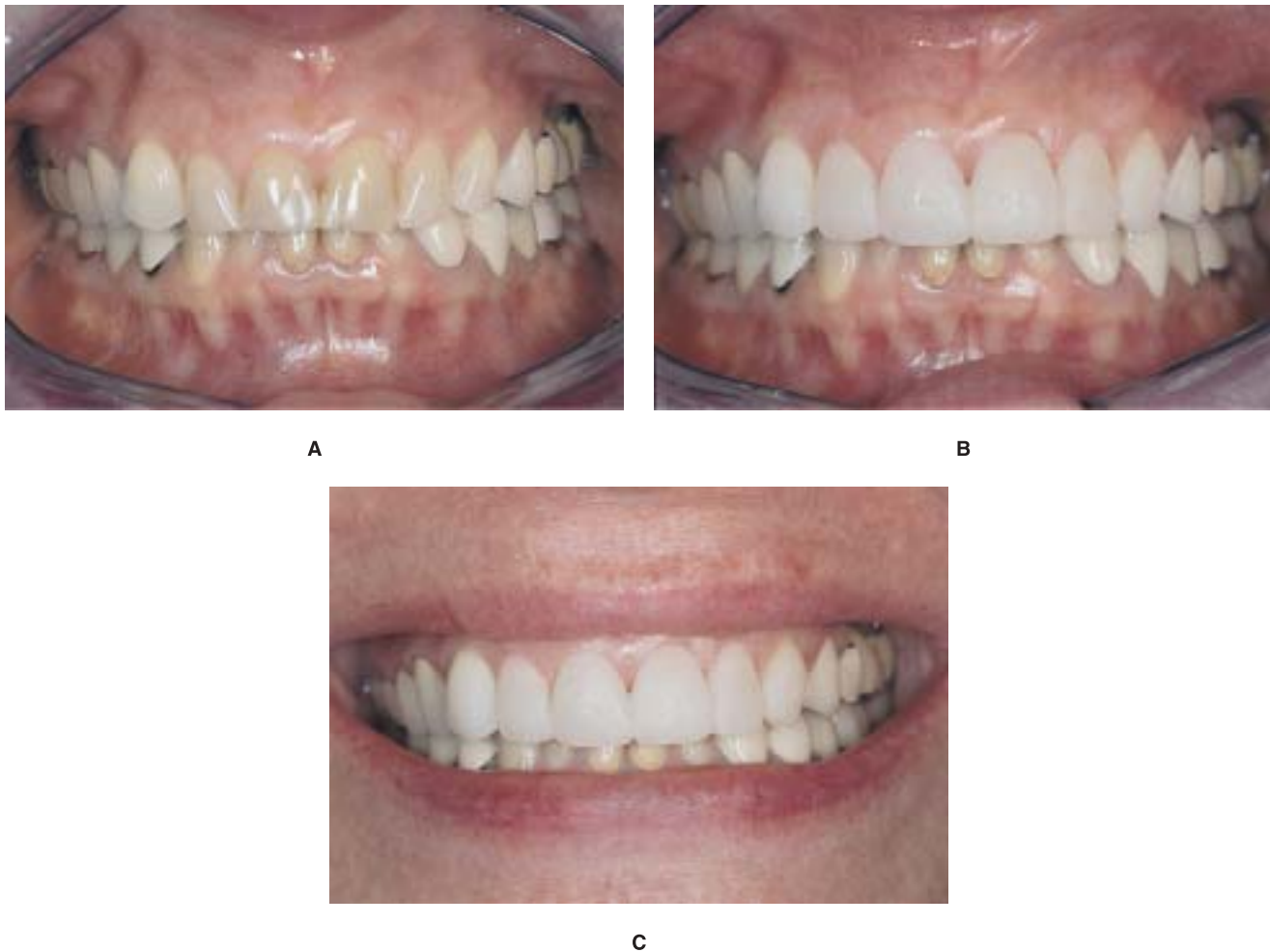

Figure 27-6. A, Preoperative worn dentition. B, Full view of composite mock-up. C, Composite mock-up of lip line smile.

#### Box 27-4 Esthetic Considerations and Ceramic Restorations

##### I. Emergency Treatment

###### A. Restore Anatomic/Clinical Crowns

- Fabrication of provisional acrylic restorations or application of composite bonding to restore form

###### B. Endodontic Treatment

- Fractured teeth
- Pulpal involvement
- Periapical infection

##### II. Initial Therapy

- Debridement of plaque and calculus deposits adherent to clinical crowns and roots of teeth or restorative materials both supra and subgingivally
- Oral hygiene instruction

##### III. Intraoral Digital Imaging and Diagnostic Mock Up<sup>37</sup>

Enables the clinician, patient, and laboratory technician to evaluate:

- The three dimensional appearance, form, and function of teeth
- The actual size, shape, and form of teeth

**Box 27-4 Esthetic Considerations and Ceramic Restorations—cont'd**

- Incisal length and incisal plane relative to lip profile<sup>108</sup>
- Location and form of the gingival topography to compliment tooth form relative to smile profile

**IV. In Anticipation of Endosseous Implant Placement**

- Placement into recently or immediately extracted tooth root(s) sites
- Augment the volume of bone and soft tissue before placing the implant

**V. Restorative Tooth Lengthening**

- Fabrication of post/cores for teeth with insufficient tooth length/retention

**VI. Surgical Tooth Lengthening**

- To improve the tooth's biomechanical profile
- To enhance retention and resistance
- To improve esthetic profile and length of tooth form

**VII. Installation of Endosseous Implants**

- To create an individual clinical crown
- After tissue healing associated with clinical tooth lengthening
- Use of surgical template to provide correct implant location and angulation
- At time of tooth extraction, with immediate placement of the provisional restoration (without opposing tooth contact)

**VIII. Uncovering of Endosseous Implants: "Two-Stage" Protocol**

- Mucogingival therapy as needed

**IX. Fabrication of Implant-Supported Provisional Restoration****X. Tooth Preparation and Impression**

- Performed using an index of the form of the teeth. On the basis of the diagnostic mock-up, the preparation of the teeth can be accurately performed; followed by a master impression technique that is predictable for the clinician.

**XI. Fabrication of Interim Provisional Restoration**

- From Bis-GMA or acrylic materials
- To restore tooth form, function, and esthetics on an interim basis

**XII. Try-in/Insertion of Ceramic Restorations:**

- Check the individual and collective fit of the restorations. Adjust the contact point or contact areas, and then use radiographic verification of seating of the restorations, to help ensure successful luting, long-term function, and maintenance of the restorations.

**XIII. Adjustment and Installation of an Occlusal Guard or Bite Platform Appliance**

- When deemed necessary

When orthodontic intervention is indicated, it generally precedes the provisional restorative phase. If the sequence is reversed, the clinical team may be involved with additional repairs and recementations. Cement washout places teeth at greater risk for development of caries, and the patient often may require a new provisional restoration before the impression phase of therapy.

After the provisional restorations are fabricated and tooth stability is achieved, the restorations can be removed

to better access the surgical field for correction of any hard and soft tissue reconstruction. Once tissue maturation has occurred and after the prognosis is established for all remaining teeth on both an individual and collective basis, subgingival preparation can be finalized and the provisional restorations relined. This is followed by completion of the fixed or fixed-removable prosthesis (Fig. 27-8).

The resective periodontal surgical approach is a predictable one. However, experimental and clinical research has shifted the focus of periodontics toward

**Box 27-5 Dental Therapy Without Implants****I. Emergency Treatments: (see Table 27-1)****II. Scaling, Root Planing, Oral Hygiene Instruction****Closed or open flap debridement**

- Mechanical debridement of calculus and plaque deposits adherent to clinical crowns and roots of teeth or restorative materials both supragingivally and subgingivally
- Removal of all chronic granulation tissue

**III. Operative Dentistry**

- Conservative control of dental caries

**IV. Orthodontic Treatment (Partial or Full Therapy)**

- Level and align teeth
- Erupt fractured or impacted teeth
- Extrude teeth to correct infrabony defects and augment the bone and soft tissue topography
- To support orthognathic correction

**V. Fabrication of Interim Provisional Restorations****Guidelines<sup>51</sup>**

- Replace missing, or recently extracted teeth, or both
- Maintain or reestablish interarch and intraarch harmony
- Assess adequacy of tooth reduction
- Determine the clinical crown profiles
- Develop therapeutic occlusal arrangement
- Control occlusal forces and assess function

**VI. Periodontal Surgical Treatments****A. Osseous Therapy**

- Regeneration and augmentation
- Regeneration of attachment apparatus of teeth
- Regeneration and augmentation of ridge deformities
- Ostectomy/osteoplasty
  - Improve bone morphology
  - Reduce pocket depth

**B. Mucogingival Therapy**

- Enhance the gingival complex around teeth and implants
- Grafting procedures (e.g., subepithelial connective tissue grafts, allogenic dermal grafts, and others)

**VII. Reevaluation****A. Establish the Prognosis of the Remaining Teeth**

- Function and esthetics
- Occlusion
- Phonetics
- Mucogingival considerations
- Emergence profiles

**VIII. Final Prosthetic Treatment**

- Fixed prosthesis
- Fixed-removable prosthesis
- Fabrication of an occlusal appliance after installation of the final prosthesis, when deemed necessary

**IX. Maintenance**

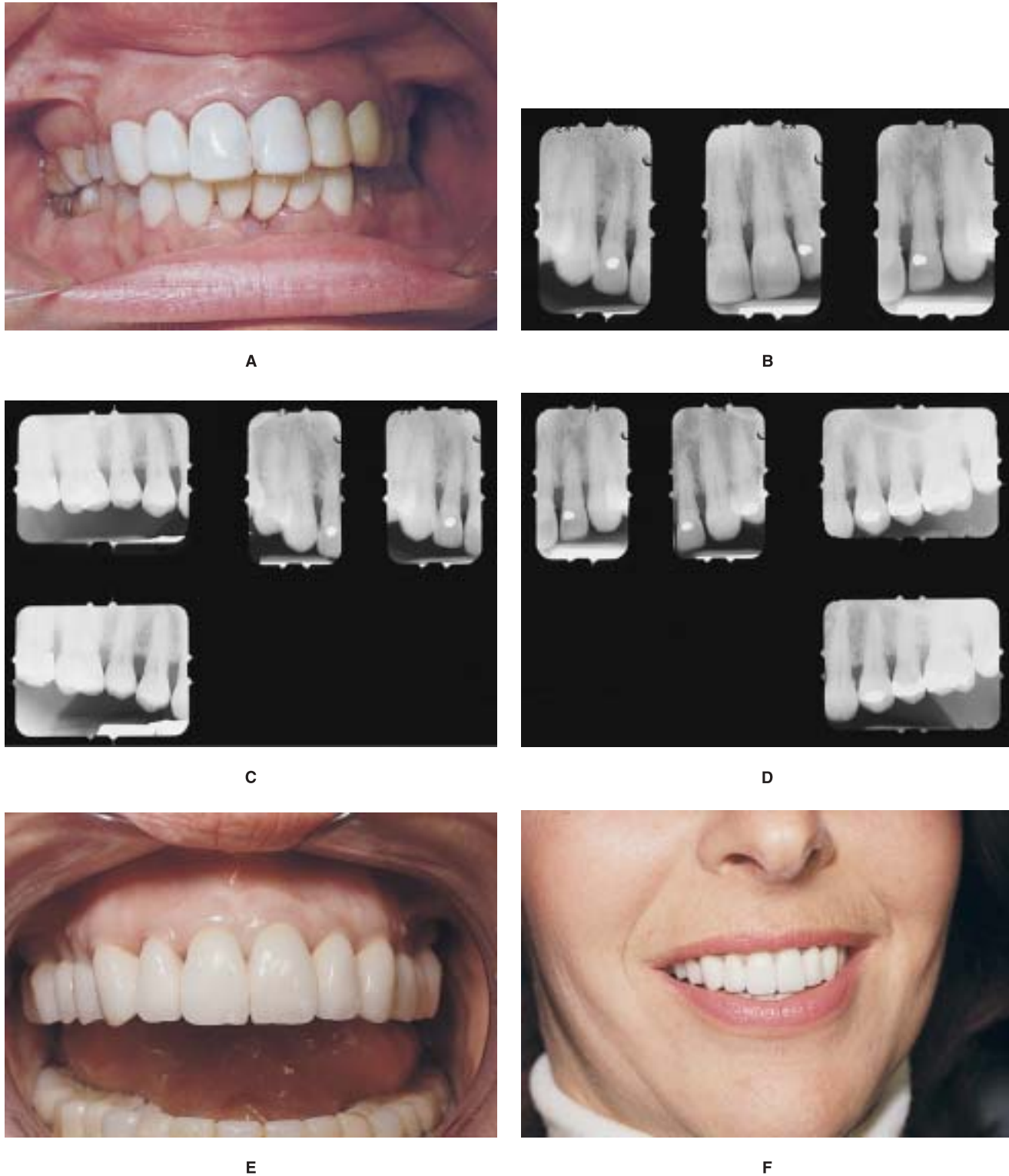increased use of guided tissue membrane techniques to regenerate desired attachment apparatus circumscribing the periodontally compromised root. This newer era of “regeneration” therapeutics represents a positive shift in treatment strategy.<sup>39</sup>

**DENTAL THERAPEUTICS: WITH IMPLANTS**

Based on longitudinal studies, the viability<sup>40-46</sup> of endosseous implants becomes an integral part of periodontal prosthesis. Implant stability and load-bearing capacity, when secured in alveolar bone, adequate in quality and quantity, will result in a functional fixed restoration. The damage associated with primary and secondary occlusal trauma on many teeth often can be reversed. Teeth that appear to have a guarded prognosis may be able to assume a useful role in the final prosthesis.

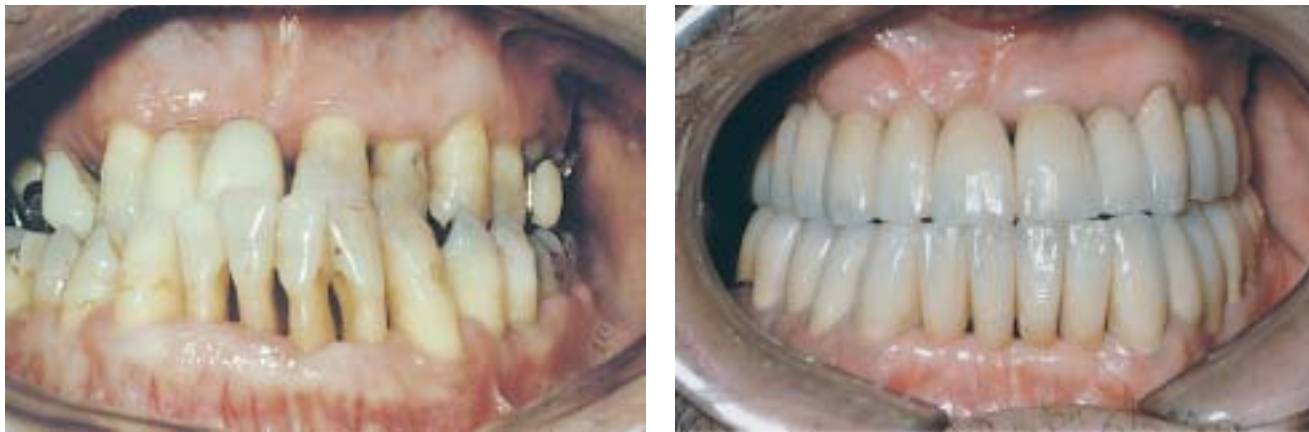During the past decade, implant restorations were reasonably acceptable from an esthetic perspective. However, in cases of advanced periodontal disease, the resorption of alveolar bone creates a significant challenge to achieve an esthetic, functional restoration. Placing implants in resorbed bone often results in long, unesthetic teeth with an adverse crown-to-implant ratio. Implant positioning is critical from faciolingual, mesiodistal, and incisoapical perspectives. It was quickly determined that the type of periodontium, whether thick-flat or thin-scalloped, significantly affects the esthetic outcome. The thin-scalloped type, with its friable gingival and osseous morphology, often results in tissue recession, ultimately exposing metal at the gingival crown margins.

Therefore, biologic and anatomic limitations such as insufficient bone, location of the maxillary sinus and the



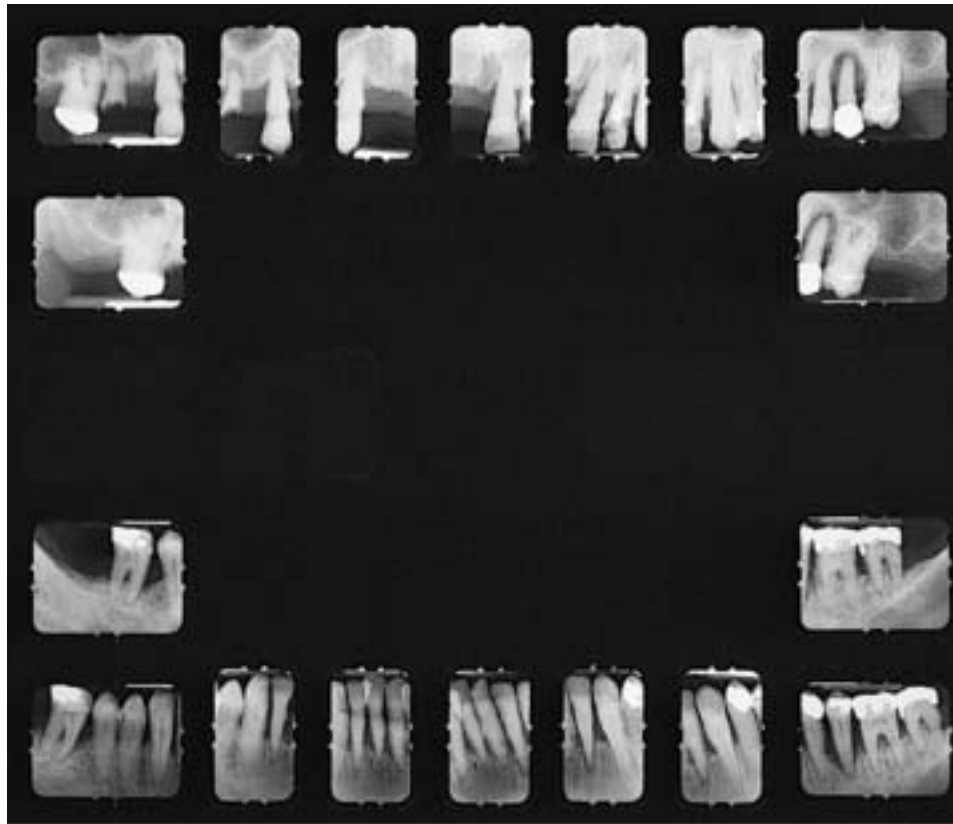
**Figure 27-7.** A, Poorly adapted composite veneers for maxillary anterior teeth, with marked gingival inflammation and generalized probing depth in the 5- to 6-mm range. B-D, Radiographic evidence of subgingival calculus accumulations and inconsistent bony margins. Resultant increase in crown-to-root ratios of maxillary anterior group of teeth. E and F, Splinted ceramo-gold-metal restorations, after healing from apically positioned muco-periosteal flap surgery to eliminate the periodontal disease and create normal topographic form, with minimal probing depth throughout. (Periodontal surgical therapy performed by Dr. Garry Miller.)





A

B



C

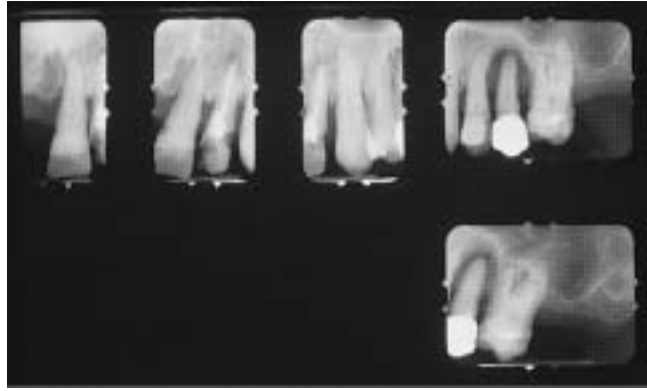
**Figure 27-8.** A and B, Class III malocclusion with severe periodontitis and occlusal trauma, as evidenced by significant loss of alveolar bone circumscribing many maxillary and mandibular teeth and associated widened ligament spaces and mobility patterns. C, Final ceramo-gold-splinted crownwork, restoring normal form, function, and esthetics.

*Continued*

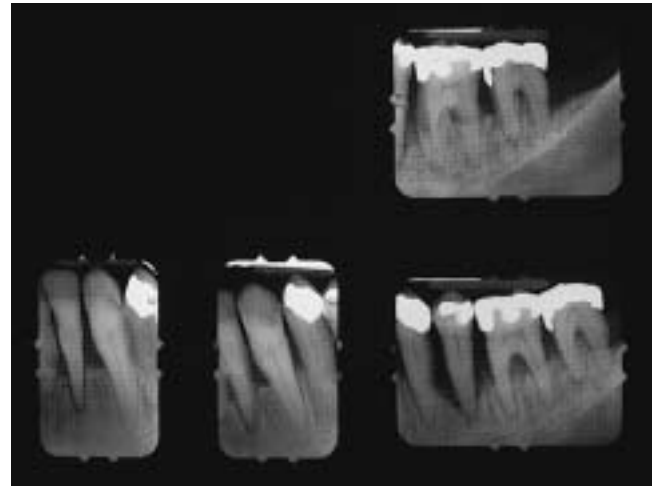
alveolar nerve, and various bone and soft-tissue deformities, must be properly diagnosed before establishing a realistic treatment plan.<sup>47-50</sup> This requires effective communication between the periodontal surgeon, the restorative dentist, and the lab technician. The dental team

must try to anticipate the size and shape of the deformity that will be created by removal of the involved teeth.<sup>51</sup>

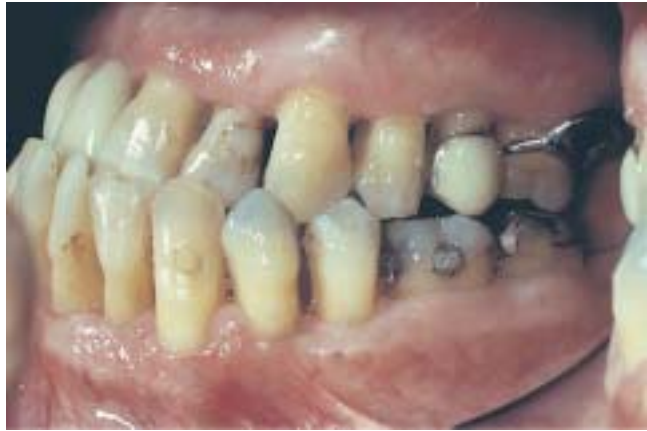Patients with advanced periodontal disorders may have compromised teeth that can be retained to offer short-term function with an interim fixed provisional



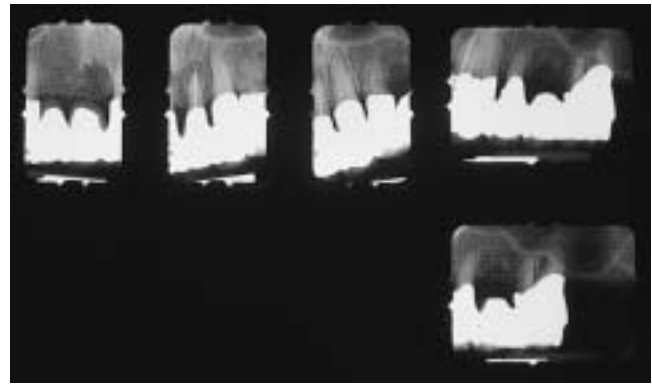
D



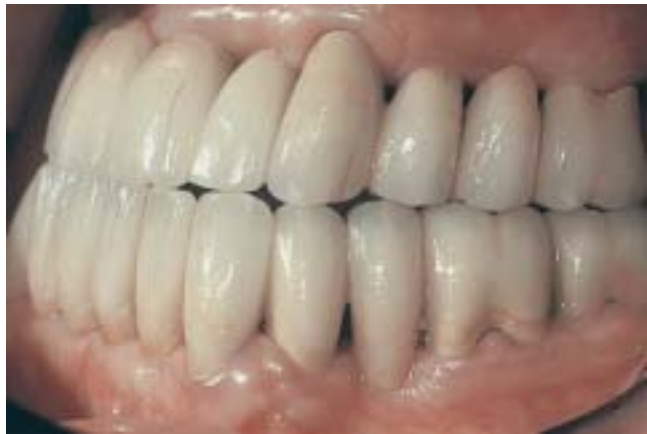E



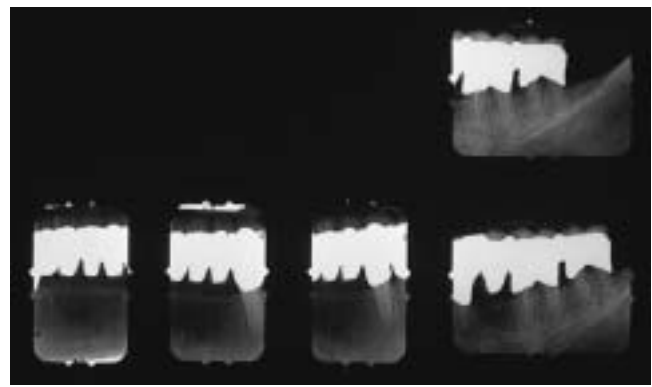
F



G



H



I

**Figure 27-8. cont'd** D-F, Left side view of dentition pretreatment with radiographic evidence of severe periodontal destruction. G-I, Final ceramogold restorations with postoperative radiographs. (Periodontal therapy performed by Dr. Michael Stiglitz.)

prosthesis rather than forcing them to rely on a removable denture. In this way, the risk for prematurely loading the implant and inducing micromotion during the initial stages of healing is reduced.<sup>52</sup> A well-designed and well-constructed interim provisional restoration is most important because the surgical procedures needed to establish the proper environment for the placement of implants increases the amount of time the patient

needs to function with the provisional restoration.<sup>53-63</sup> (Box 27-6).

The compromised teeth that remain may be removed at a later stage in favor of additional endosseous implant support, as dictated by the biomechanical needs of the final restoration. Appropriate periodontal therapy is performed for all teeth that have a favorable prognosis. Either regenerative approaches<sup>38</sup> or pocket reduction<sup>64-66</sup>

#### Box 27-6 Dental Therapy with Implants

##### I. Emergency Treatments (see Table 27-1)

##### II. Scaling, Root Planing, Oral Hygiene Instruction

###### Closed, Open Flap Procedures

- Mechanical debridement of calculus and plaque deposits adherent to clinical crowns and roots of teeth or restorative materials both supragingivally and subgingivally
- Removal of all chronic granulation tissue

##### III. Operative Dentistry

- Conservative control of dental caries

##### IV. Orthodontic Treatment

- Level and align teeth—improve tooth position
- Erupt fractured or impacted teeth—rebuild/reposition bony complex
- Extrude teeth to correct infrabony defects and augment the hard and soft tissue topography
- To support orthognathic correction

##### V. Fabrication of Interim Provisional Restoration

###### Guidelines

- Allow for extraction of hopeless teeth
- Maintain or reestablish interarch and intraarch harmony
- Assess adequacy of tooth reduction
- Determine the clinical crown profiles
- Develop therapeutic occlusal arrangement
- Control occlusal forces and assess function
- Allow for fabrication of “Diagnostic Template” with markers for radiographic analysis

##### VI. Periodontal Surgical Treatments

###### A. Osseous Therapy

- Regeneration and augmentation
  - Regeneration of the attachment apparatus of teeth and bone augmentation of deformed alveolar ridges
- Ostectomy/osteoplasty
  - Improve bone morphology
  - Reduce pocket depth

###### B. Mucogingival Therapy

- Enhance the gingival complex around teeth and implants
- Grafting procedures (e.g., subepithelial connective tissue grafts, allogenic dermal grafts, and others)

##### VII. Bone Grafting, Sinus Bone Augmentation Procedures

- Dictated by the need to properly place implants

##### VIII. Fabrication of Surgical Template

- To guide implant placement—based on clinical and radiographic interpretation

**Box 27-6 Dental Therapy with Implants—cont'd****IX. Implant Placement**

- Existing alveolar bone sites or healed extraction sites
- Bone augmentation sites (e.g., sinus, alveolar ridges)
- Fresh extraction sites

**X. Interim Maintenance (to Facilitate Healing)****A. Surgical Sites**

- Continue to evaluate the healing and treat any complications (e.g., exposed membranes, incision dehiscence, loose cover screws)
- Interim provisional prosthesis
- Repair broken acrylic joints
- Replace soft reline materials
- Maintain and monitor transitional implants

**XI. Transitional Implant-Assisted/Supported Restoration**

- Placement of transepithelial healing components at the second-stage procedure
- Selection of implant abutments
- Conversion of existing provisional to implant-assisted/supported restoration
- Fabrication of new implant provisional restoration or new implant and tooth-assisted provisional restoration

**XII. Reevaluation**

- Stability of implants and remaining teeth
- Occlusal vertical dimension
- Phonetics
- Esthetics
- Proper emergence profiles of crowns for teeth and implants

**XIII. Prosthetic Treatment**

- Implant-assisted
  - Fixed prosthesis
  - Fixed-removable prosthesis
- Implant-supported
  - Fixed prosthesis
  - Fixed-removable prosthesis
  - Fabrication of an occlusal appliance after the final prosthesis is installed, if deemed necessary

**XIV. Maintenance**

and clinical crown exposure procedures should be rendered before endosseous implant installation.

Orthodontic treatment may be necessary to establish adequate space before placing an implant. Therefore, tooth movement should be initiated during the early stages of treatment. In some situations, with flared maxillary anterior teeth and few posterior teeth, implants may be placed first and used as an anchorage mechanism to retract and align the remaining teeth. One must not minimize the value of orthodontics. After complete debridement of the root surface(s) adjacent to periodontal bony defects, mechanotherapy may help to reduce and to modify the size and shape of angular osseous deformities, often through eruption/extrusion.<sup>67-69</sup> The improvement in hard and soft

tissue topography allows the newly regenerated bone to successfully receive endosseous implants. Forced eruption of hopeless teeth is currently used to alter the soft and hard tissues before placing implants. Also, orthodontic extrusion is used to recreate lost interproximal papillae (see Chapter 28).

**Outcome-Based Planning****Interim provisional restoration**

The interim restoration may be designed in several different ways. One approach is to modify an existing bridge or splint, reline the crowns on selected natural teeth, and convert other crowns to pontics as necessary. With a paucity of strong, well distributed natural teeth, the



existing rigid metal framework can better resist normal occlusal forces and help to prevent prosthesis fracture.

The removable interim prosthesis is less desirable for preserving masticatory function. It should be used when the support provided by the remaining teeth is compromised and the number and distribution of teeth is insufficient to allow for the use of a fixed prosthesis. If a removable prosthesis must be used, it is imperative that the restorative dentist evaluates the edentulous areas frequently and replaces the soft liner material when it becomes hard or brittle or precipitates a pressure ulceration of the soft tissue. Currently, there are “temporary” implant systems that preclude the use of the removable appliance. It allows the clinician to use a fixed “mini-implant” supported restoration throughout the phase of implant osteointegration.<sup>70-75</sup>

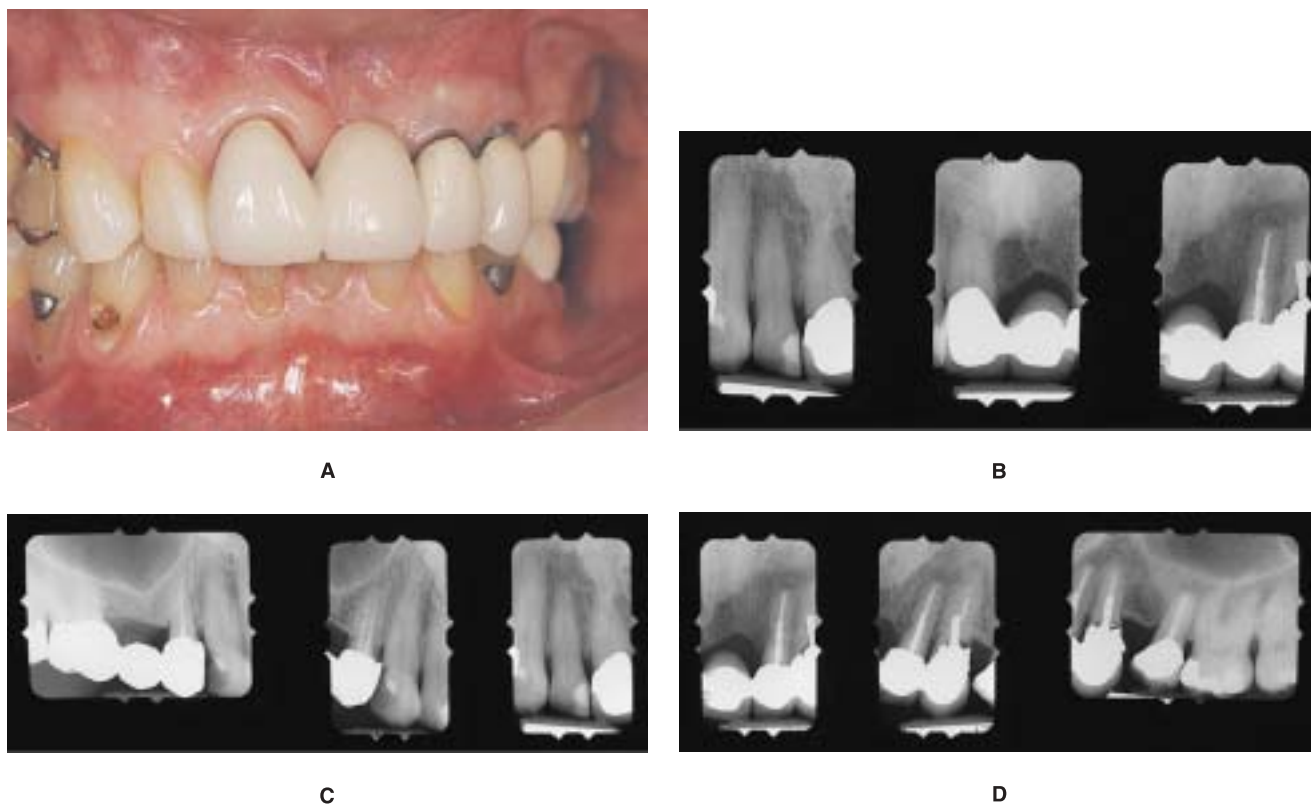
Ideally, a fixed provisional restoration should be made from a diagnostic wax-up, incorporating all of the esthetic and functional characteristics. Any preexisting limitations should be corrected to allow the prosthesis to serve as a blueprint of the final prosthesis. (Fig. 27-9)

With advanced periodontal disease, the maxilla generally resorbs apically and palatally; therefore, the mandible

appears to be much larger than the maxilla. When all the maxillary teeth are eventually lost and the edentulous cast is mounted on an articulator, it appears as if the patient has a prognathic relationship. However, this is not a true prognathic arch profile, but rather a result of the bone resorption of the maxilla. And if the patient desires implants and a fixed restoration this<sup>76</sup> becomes a surgical and restorative challenge. The clinician(s) must know before the implants are placed how this occlusal disparity will be corrected in the final prosthesis. In this situation, the volume of available bone is significant to the long-term survival of implants because of the exaggerated anterior-posterior discrepancy.

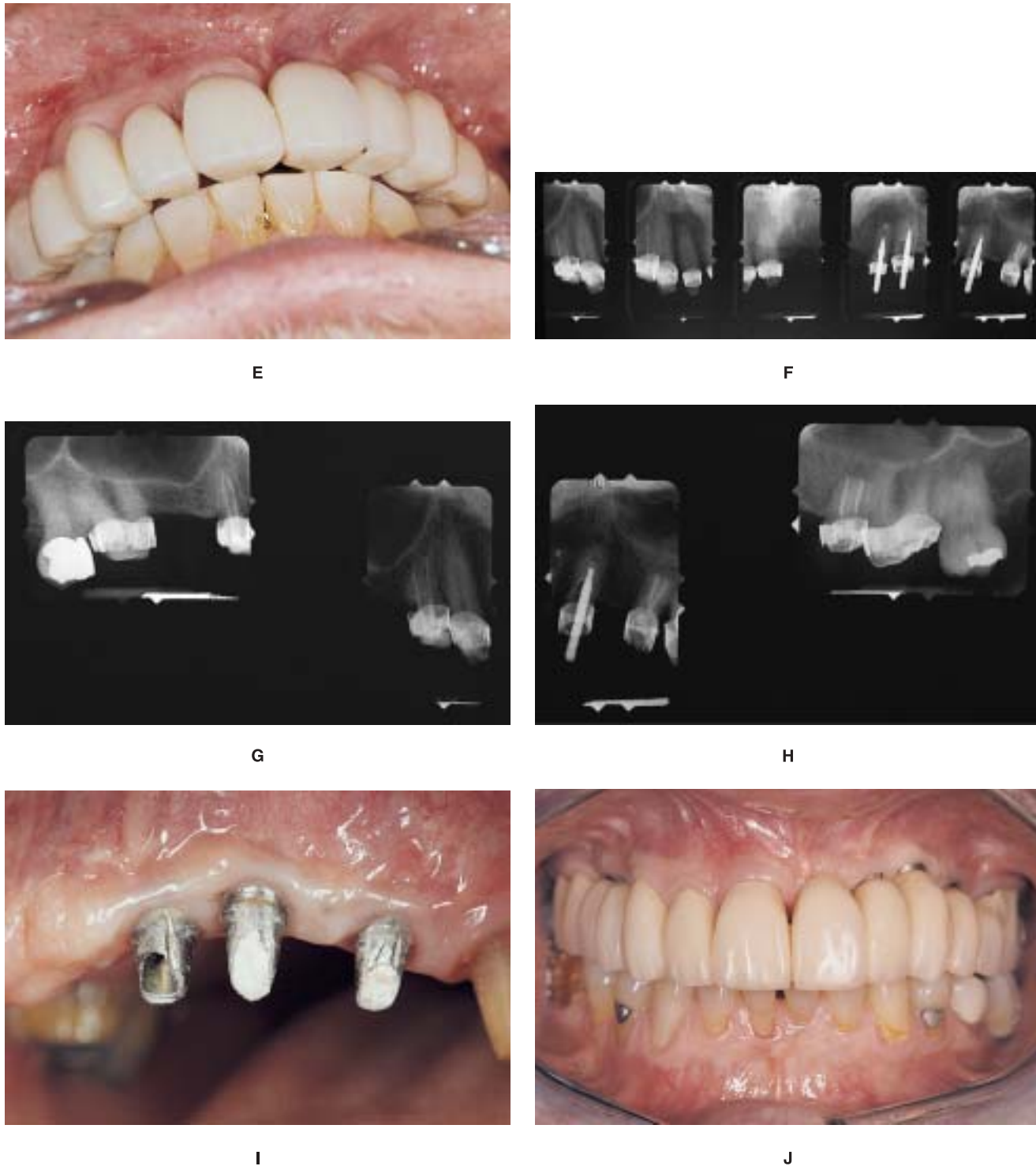It is wise and judicious to fabricate a temporary appliance simulating the final restoration before any surgical procedures. This is essential when the clinician is contemplating a change in the occlusal vertical dimension. This alteration will change the faciapalatal relationship of the mandible as it relates to the maxilla.

The lip line esthetic diagnosis, as well as the lip support, will influence the decision to fabricate a fixed or removable prosthesis. A simple and effective way to make a reasonable esthetic appraisal of the final prosthesis is



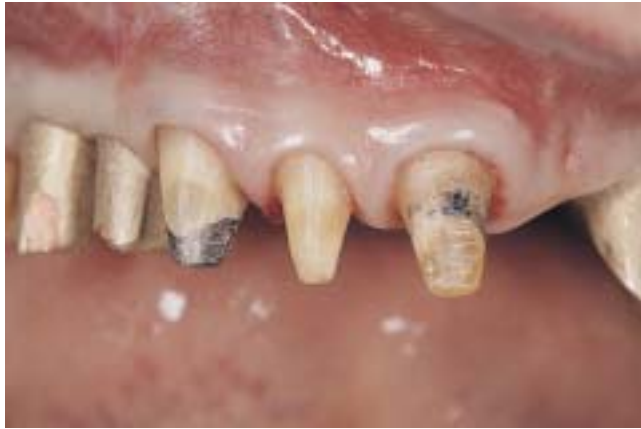**Figure 27-9.** A, Pretreatment Class II, division I malocclusion with failing crown and bridgework—a result of caries, post/core failures, and periodontitis. B-D, Pretreatment radiographs.

*Continued*

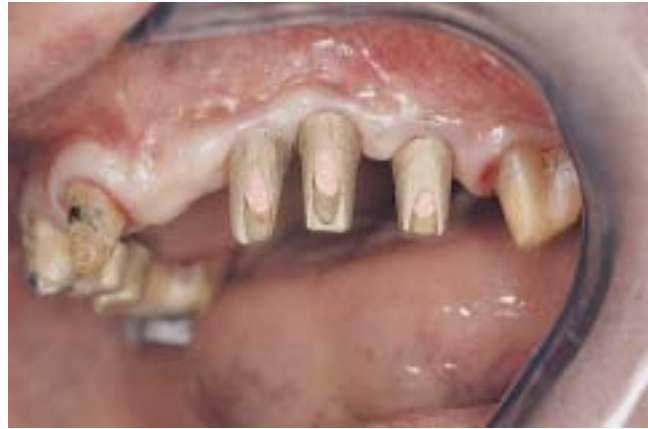

**Figure 27-9. cont'd** E, Fabrication of acrylic provisional restorations. Note the marked anterior platform created to provide both centric holding area and necessary anterior guidance (socket preservation by Dr. Karl A. Rose). F-H, Radiographs of tooth preparations after fabrication of provisional restorations. Tooth preparations and temporary transitional implant abutments. I, After second stage surgical implant exposure, temporary titanium implant abutments are machined and connected to the implant bodies, followed by relining of the existing provisional restoration (socket preservation and subsequent implant placement performed by Dr. Karl A. Rose). J, Transitional acrylic provisional restorations supported by teeth and implant abutments.

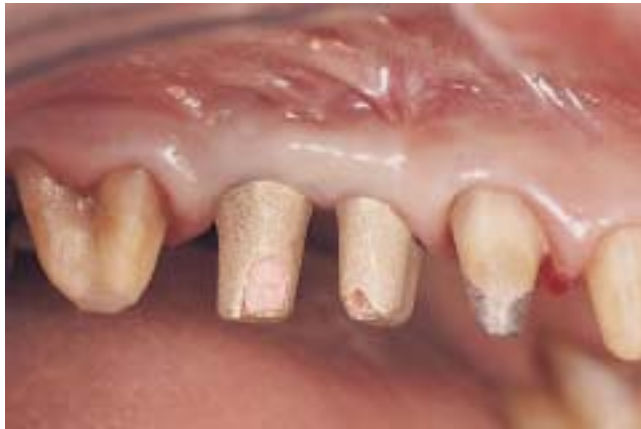*Continued*



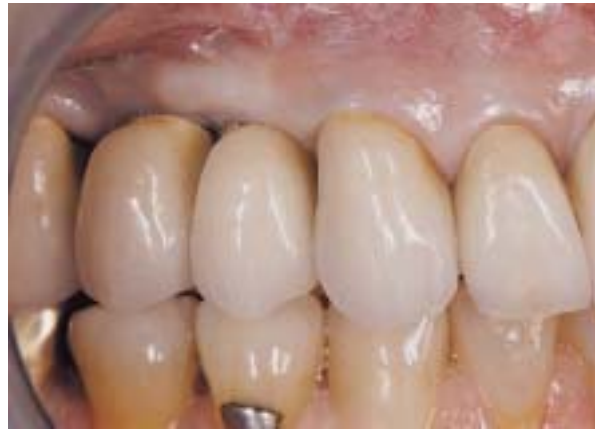K



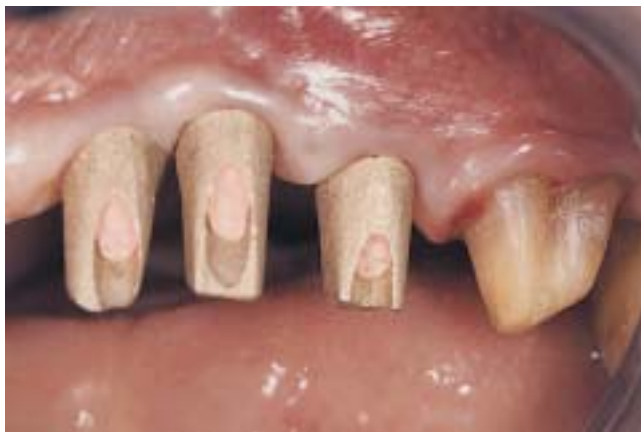L



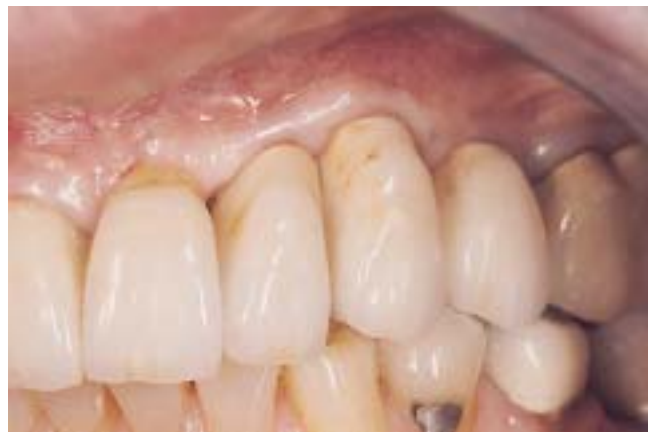M



N



O

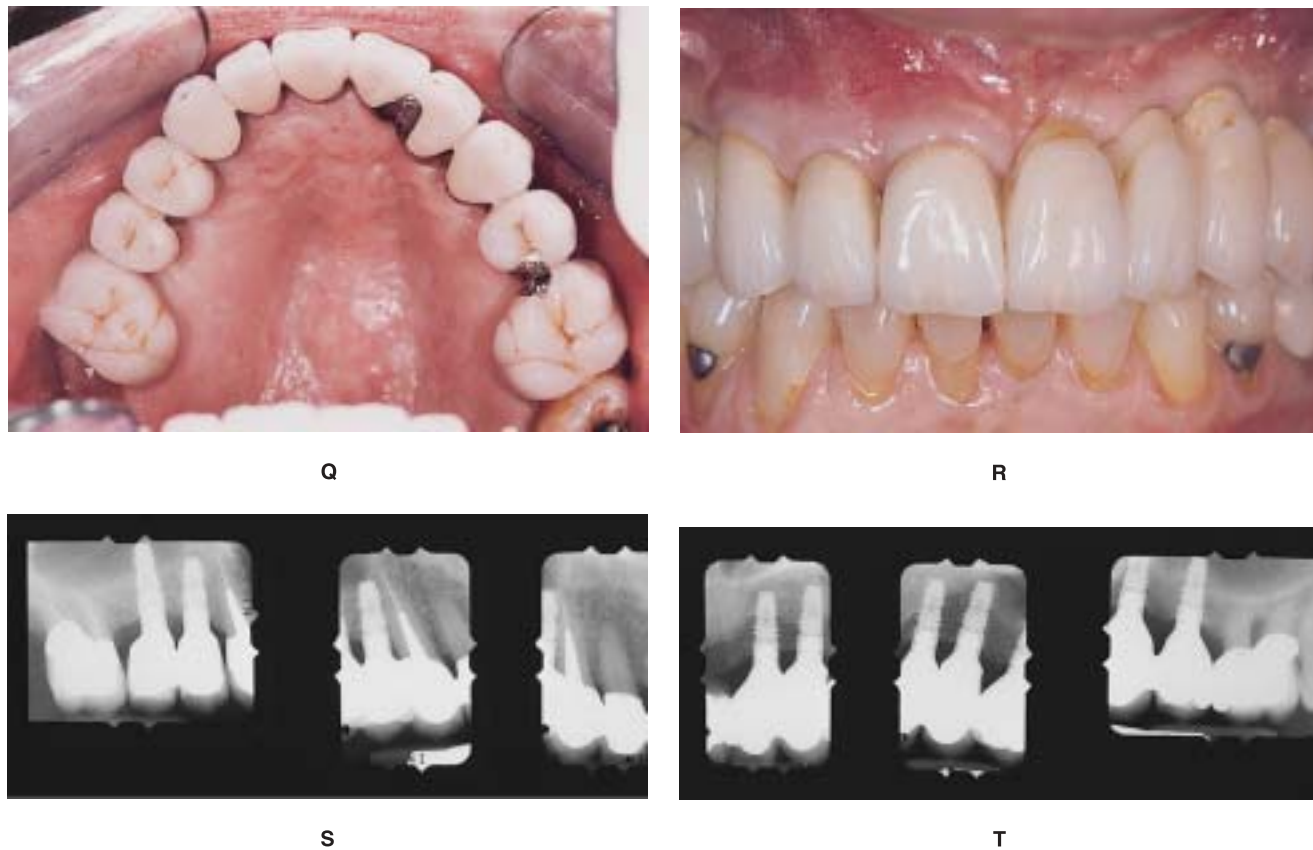


P

**Figure 27-9. cont'd** K and L, Gold implant abutments screw-retained and sealed with gutta percha. M, Final gold implant abutments at former tooth sites #4 and #5. N, Ceramo-gold implant crowns and their relation to the implant abutments. O, Final gold implant abutments at former tooth sites #10, #11, and #12. P, The implant crowns at former tooth sites #10, #11, and #12 have been created with ceramic root form to address the loss of residual ridge height. The final prosthetic replacement of both the anatomic crown and anatomic root is classified by Misch as the FPII<sup>109</sup> prosthesis.

*Continued*





**Figure 27-9. cont'd** Q, Occlusal views of the final ceramo-gold implant-supported and tooth-supported restorations. R, Final ceramo-gold implant-supported and tooth-supported crownwork. S and T, Final radiographic appearance of completed maxillary restoration.

to evaluate the appearance of the patient's existing prosthesis. Assuming that it is acceptable to the patient and the dentist, it is wise to duplicate the existing prosthesis and evaluate the patient's profile. If the appearance is the same as the original restoration, it can be assumed that the teeth are supporting the lip. In this situation, it is likely that an acceptable fixed restoration can be made. Conversely, if the lip "collapses in", the final prosthesis will likely require some form of labial support, often necessitating a removable prosthesis. A fixed restoration would likely be unsatisfactory.

The trends that have brought dentistry to its current level of esthetic sophistication require the clinician to predict the outcome before implants are placed. If the esthetic evaluation is inaccurate, the final result will be less than desirable to the patient and the dentist.

#### Diagnostic and Surgical Templates

A diagnostic template with radiographic markers, like the surgical template, may be fabricated to assist the surgeon and restorative dentist in analyzing the available bone to place the implants. This is accomplished by using CAT radiography before implant surgery.<sup>77</sup>

The surgical template, a guide to surgical implant placement, is fabricated from either a diagnostic wax-up or, preferably, a stone model of the functioning provisional restoration.

After placing the provisional restoration intraorally, impressions are made of both the prosthesis and the underlying edentulous ridges and tooth preparations. Stone models are made and an acrylic shell of the restoration is cured on a model of the remaining prepared or unprepared teeth, or both. Locations and axial alignments are carefully planned with the surgeon and are carved into the acrylic template to anticipate implant placement.

Although a lingual or palatal approach is commonly used to design the surgical guide, a facial approach also may be considered. This will provide the surgeon with an accurate visualization of the ideal implant sites, the desired path of abutment emergence, and the axis orientation in relation to the final prosthesis. The ability to perform surgical procedures demands direct access, which is provided by removal of the provisional interim restoration. The surgeon can orient the surgical template by securing it to the existing teeth, and prepare the osteotomy to properly position the implants.



Significant progress in biotechnology, radiology, and computer technology have allowed for more accurate diagnosis and treatment planning. This has recently resulted in the construction of three-dimensional bone models, stereolithography<sup>78</sup> and navigational surgery to position endosseous implants with greater precision (Fig. 27-10).

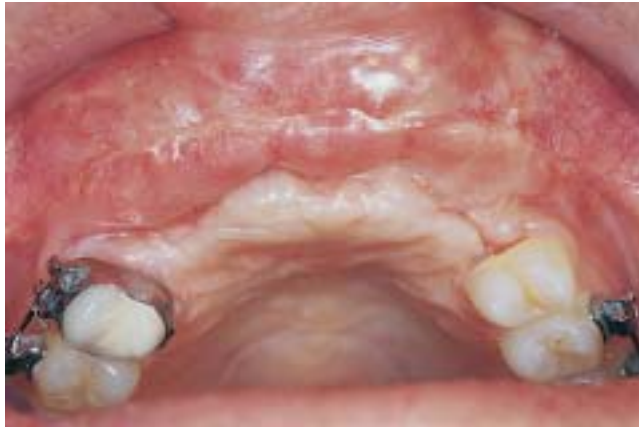### Considerations at the Surgical Phase

The well-organized treatment plan may require various scenarios to place endosseous implants into bone where teeth still exist in areas of ridge deformity.

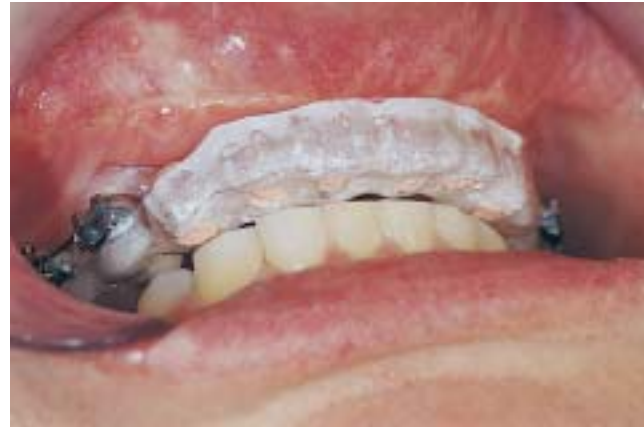Where implant placement is anticipated, the teeth to be extracted usually are removed when the provisional restoration is inserted. The newly formed bone in the recent extraction sites is considered to be an excellent source of pluripotential cells to promote successful

osseointegration. Simultaneous extraction of the tooth and placement of the implant shortens the duration of treatment.

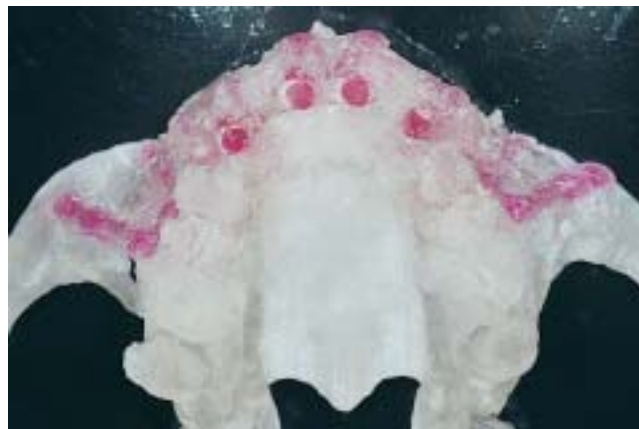In an effort to more precisely determine the quality of the alveolar bone for immediate implant placement and to minimize the overall maturation phase, the teeth may be sectioned horizontally at their gingival margins or at the height of the alveolus.<sup>79</sup> The pulps should be extirpated, the canals medicated and sealed, and provisional restorations fabricated leaving these tooth roots for the surgeon to extract at the time of implant installation. This avoids interference with early socket healing and precludes the risk for additional crestal bone resorption of the healing socket.<sup>80</sup> The surgeon will decide whether to extract and immediately place an implant into the socket. However, the surgeon may prefer to extract the



A



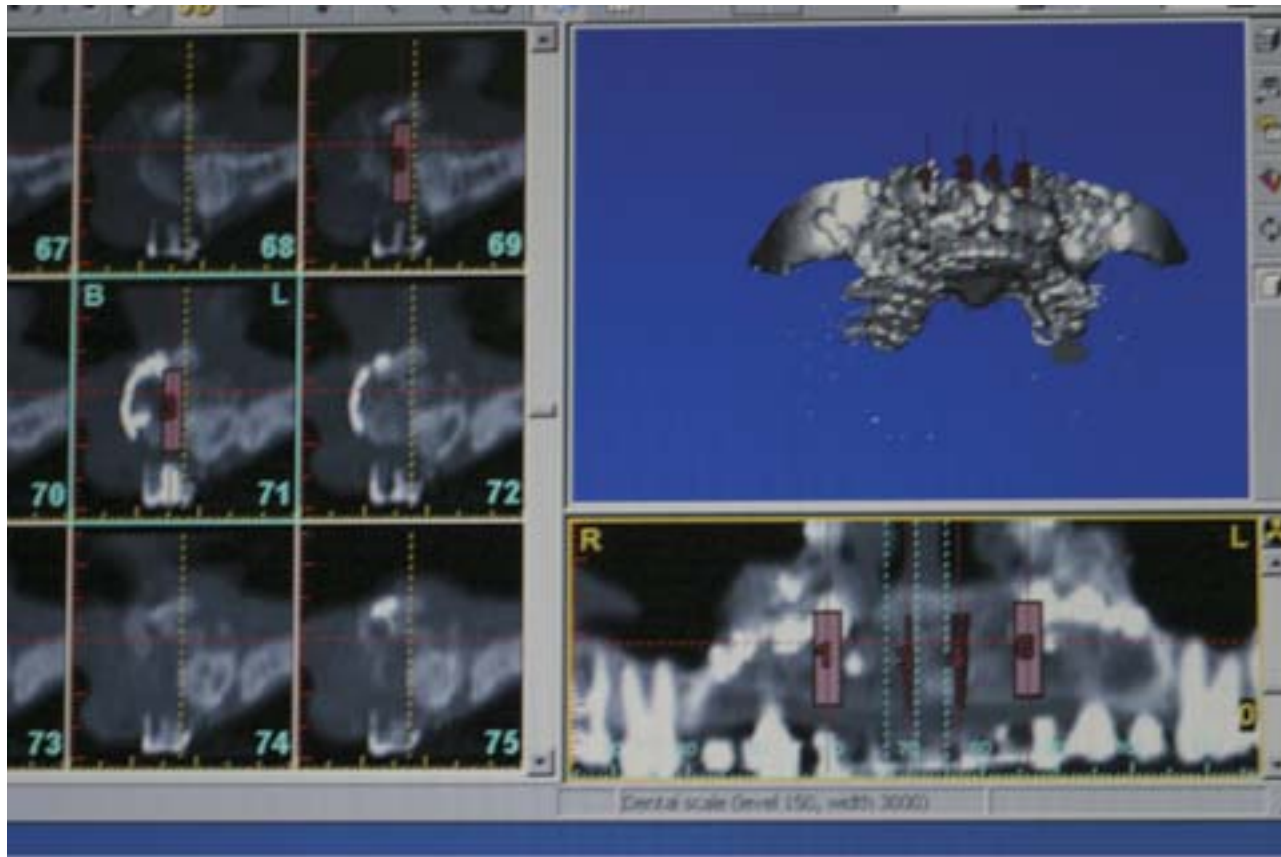
B



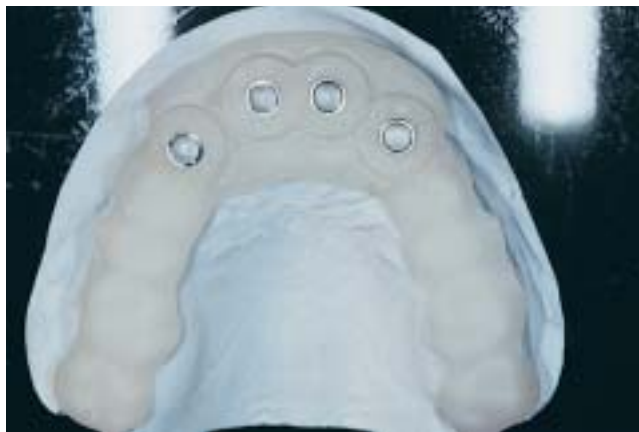C

**Figure 27-10.** A, Premaxilla after LeFort I osteotomy, with inlay graft increasing ridge height by 7 mm. B, Diagnostic template using gutta percha markers and barium sulfate to locate endosseous implants in premaxillary region. C and D, Simulation of endosseous implant installation into four available premaxillary sites, as determined by evidence of bone on the computed axial tomography (CAT) scan images.

*Continued*



D



E



F

**Figure 27-10. cont'd** E, Creation of three-dimensional maxillary bone model from CAT scan imaging. F, Surgical template with titanium cylinders to locate the implant sites with surgical precision.

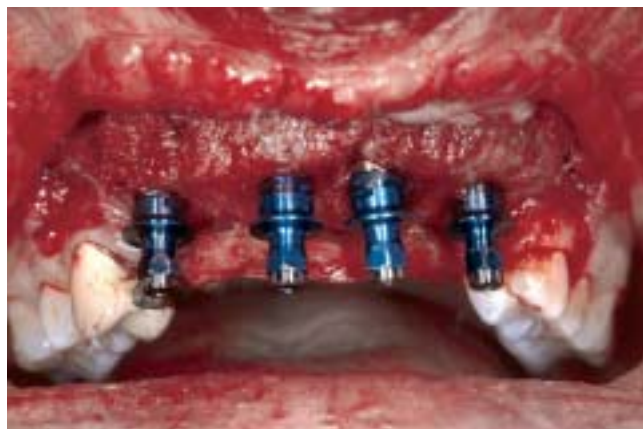*Continued*

tooth, place a bone graft and membrane, and allow it to heal 3 to 4 months before placing an implant.

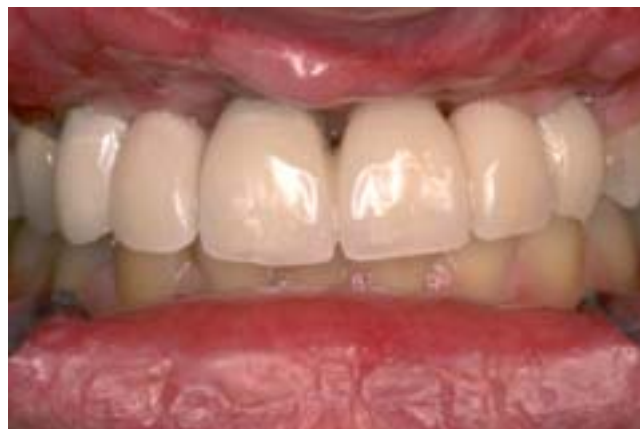If an edentulous ridge is modestly deformed and the site has been planned for implant placement, the surgeon may elect to position the implants at an angle that corresponds

to the ideal final restoration. If a dehiscence or fenestration occurs, it can be corrected by placing a bone graft and barrier membrane.<sup>81</sup>

Dental implant placement in the atrophic or deformed alveolar ridge can be a surgical challenge (see Chapter 26).



G



H

**Figure 27-10. cont'd G and H, Surgical endosseous implant placement based on CAT scan technology and stereolithography.**

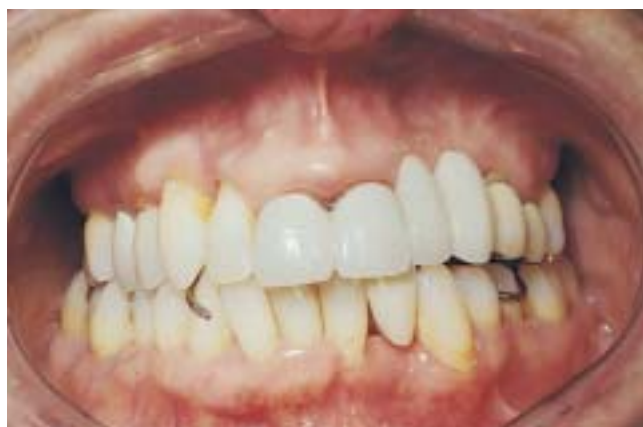Alveolar bone augmentation is currently accomplished with guided bone regeneration techniques,<sup>63,82,83</sup> sinus bone augmentation,<sup>84</sup> bone grafting,<sup>85-87</sup> and alveolar distraction osteogenesis.<sup>88</sup> Two or more surgical interventions are frequently required to correct a major ridge deformity.<sup>63,82,83</sup> First, the ridge must be reconstructed to a more normal anatomic form and size,<sup>77</sup> followed by implant placement and soft tissue augmentation<sup>89,90</sup> (Fig. 27-11).

Depending on the extent of the original ridge deformity, the surgical bone augmentation procedure can be relatively successful at restoring the bony contour to the following levels: Class I, 1 mm to 2 mm apical to the cemento-enamel junction (CEJ) level of the adjacent teeth; Class II, 3 mm to 4 mm apical to the CEJ level of the adjacent

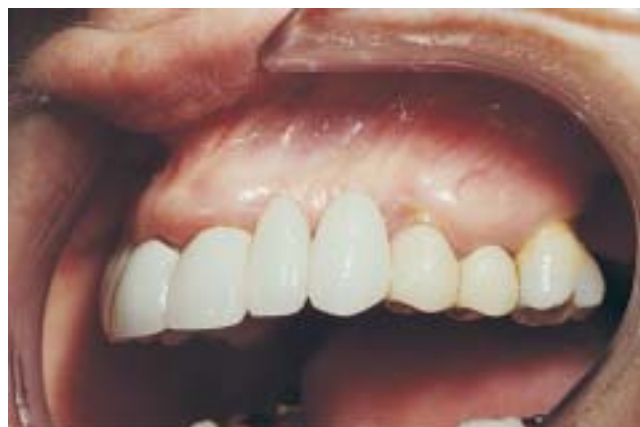teeth; Class III, 5 mm or greater, apical to the CEJ level of the adjacent teeth.<sup>77</sup>

In reconstructing the deformed ridge to a Class I bone level, a normal overlying soft-tissue profile will often be created. For the Class II bone level, where there is still some horizontal and vertical deficiency, soft-tissue augmentation by means of connective tissue grafts,<sup>89,90</sup> autogenous grafts (free or pedicle), or repositioning of the gingival complex, may mask the bony deficiency and create the appearance of normal topography.<sup>77</sup>

For the Class III level defect, prosthetic materials are frequently required to restore the hard-tissue and soft-tissue deformities and simulate the Class I reconstructed profile, which otherwise may be compromised in both height and width<sup>77</sup> (Fig. 27-12).



A

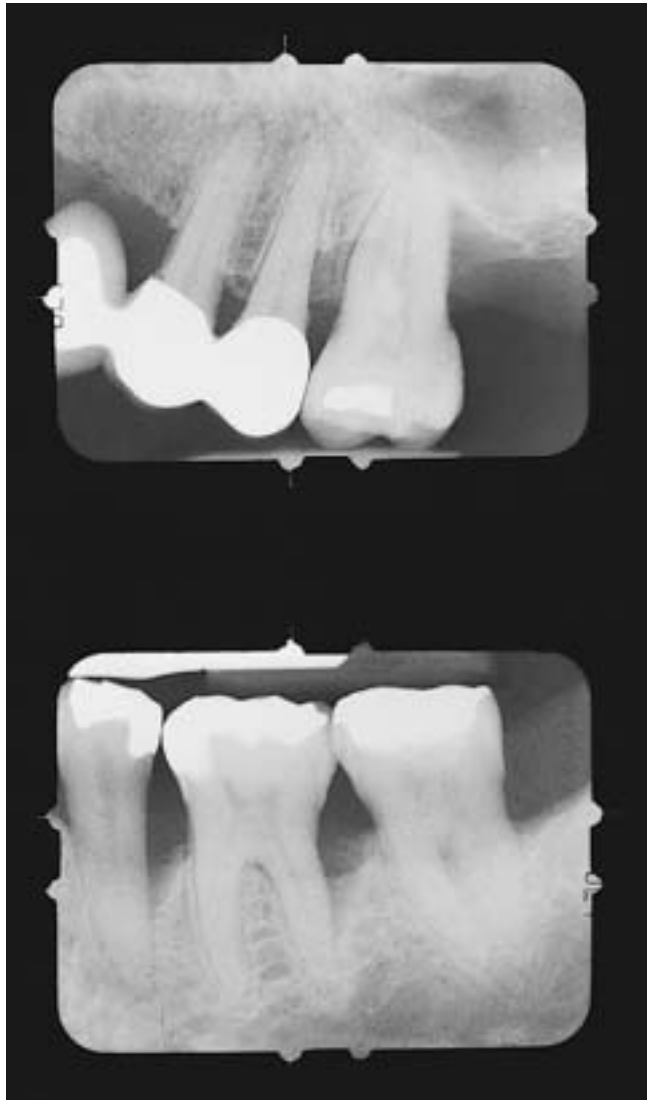

B

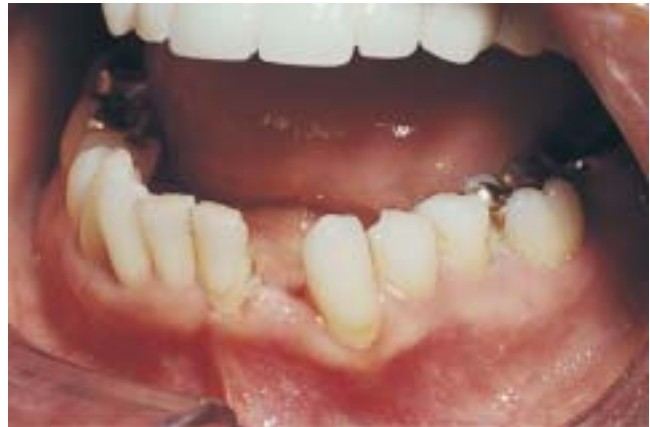**Figure 27-11. A, Clinical preoperative view. B-D, Preoperative views and radiographs reveal severe loss of periodontal support with ridge deformities and deep infrabony defects.**

*Continued*

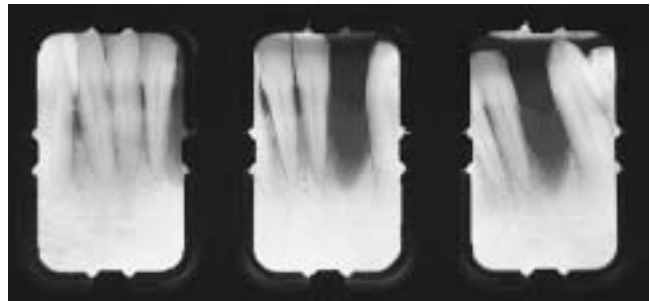




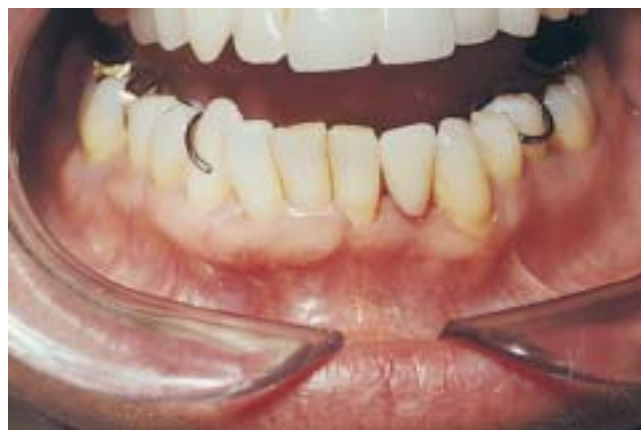C



D



E

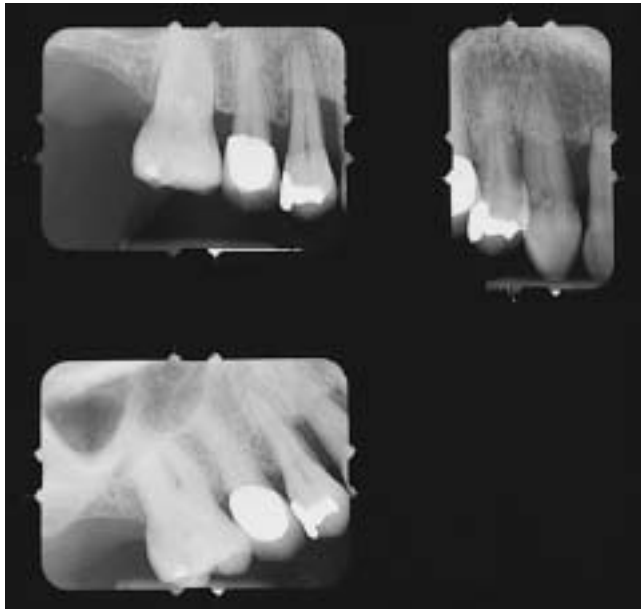


F

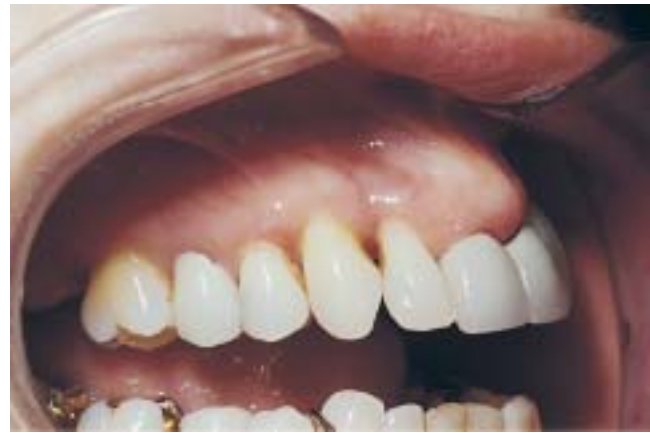Figure 27-11. cont'd E and F, Preoperative view and radiographs show severe loss of periodontal support with ridge deformities.

Continued

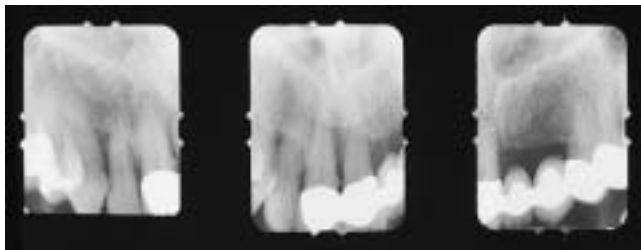



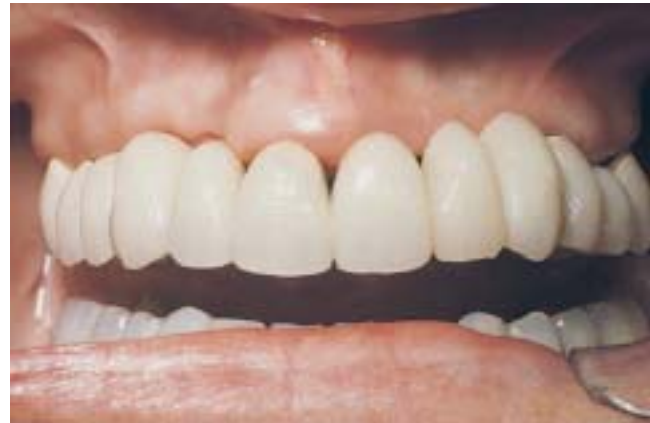G



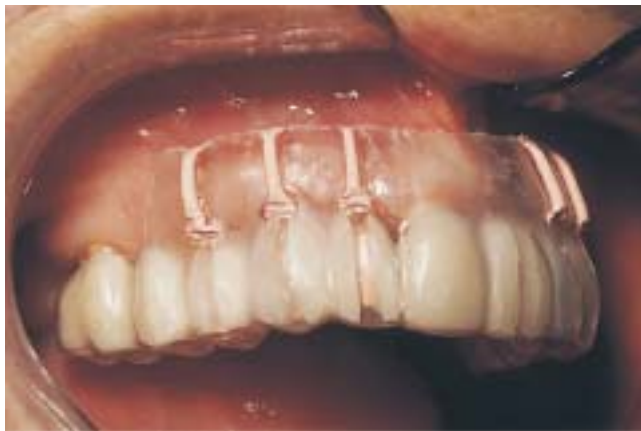H



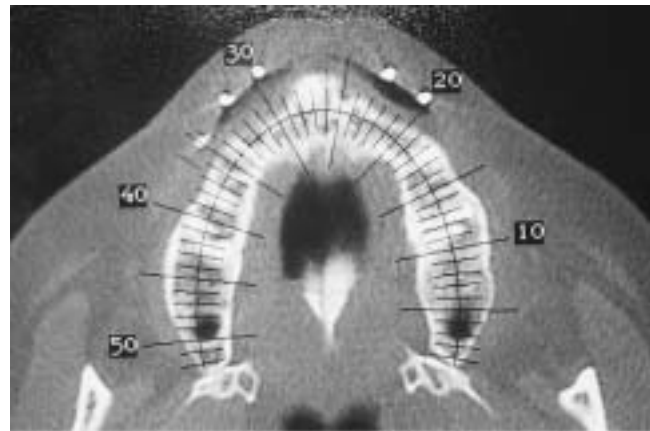
I



J



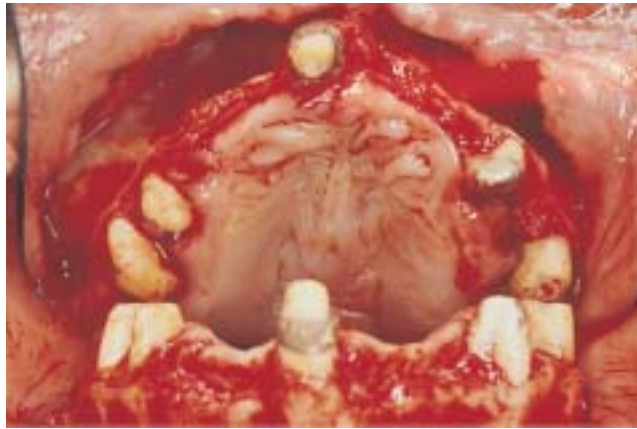
K



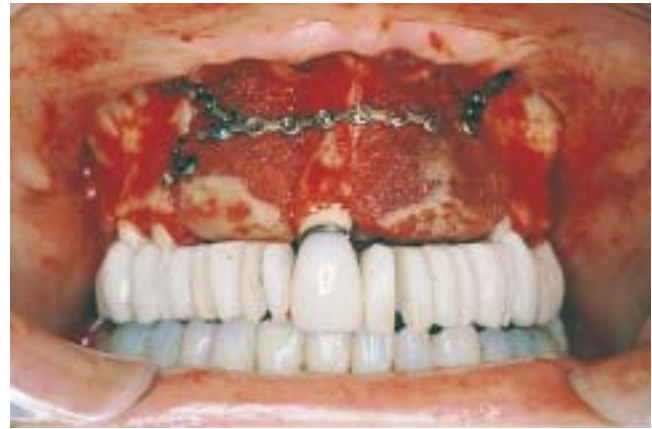L

**Figure 27-11. cont'd** G-I, Preoperative views and radiographs show severely periodontally compromised teeth #5, #6, and #7. J, Fabrication of maxillary provisional acrylic restorations simultaneous with extraction of teeth #5, #6, #7, #9, and #13. K, Diagnostic template with gutta percha markers for CAT scan. L, Diagnostic template demonstrates the lack of available bone for endosseous implant placements, as evidenced by the voids on the stone model in the premaxilla and on the radiographic CAT scan.

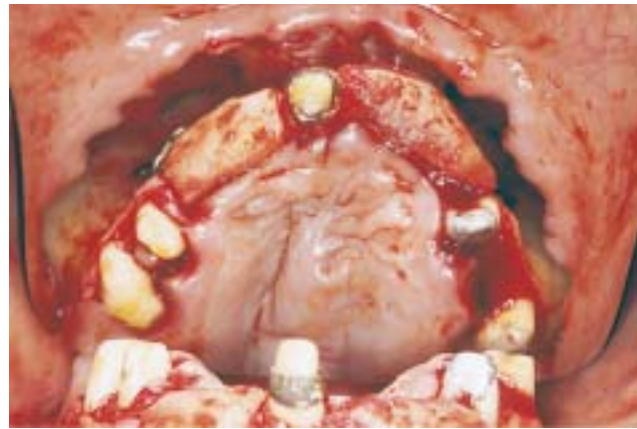
*Continued*



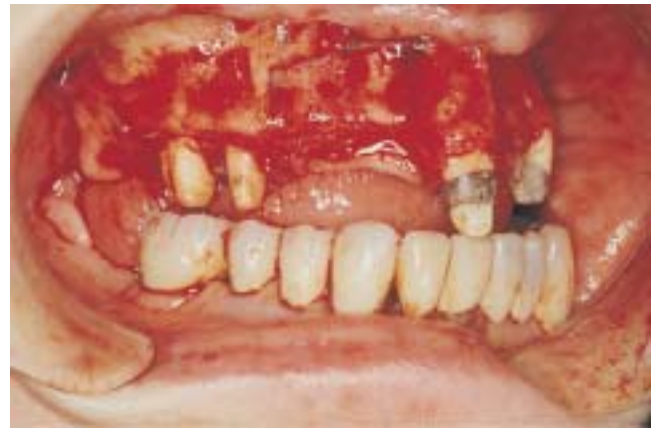M



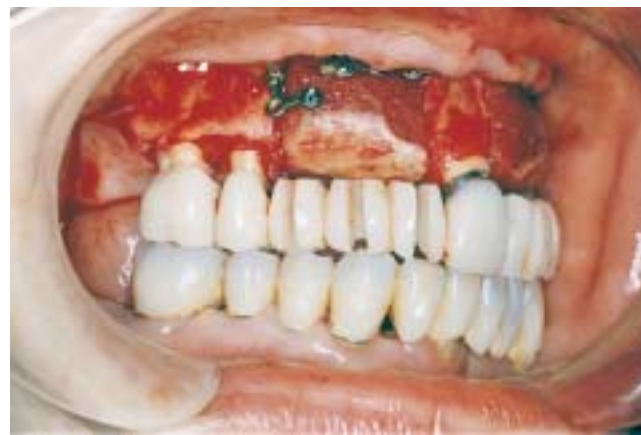N



O



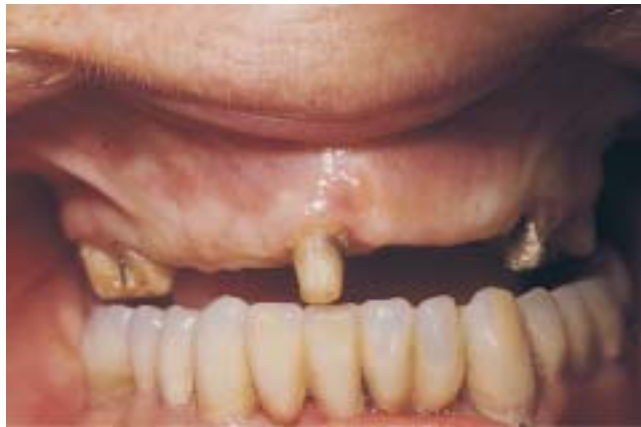P



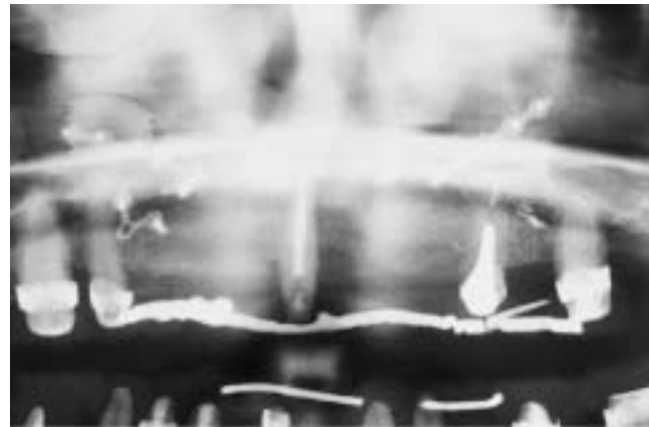
Q

**Figure 27-11. cont'd** M-O, Iliac crest bone grafting, mortised into the upper right and upper anterior residual ridges to restore horizontal and vertical component of bone loss (performed by Dr. Jeffrey Posnick). P and Q, Views of onlay graft of upper right side with fixation (performed by Dr. Jeffrey Posnick).

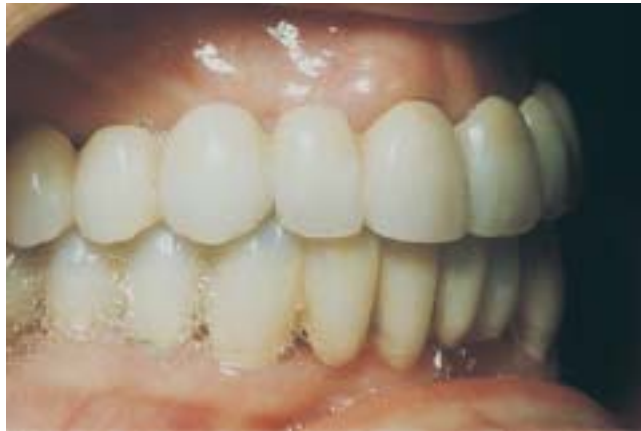*Continued*



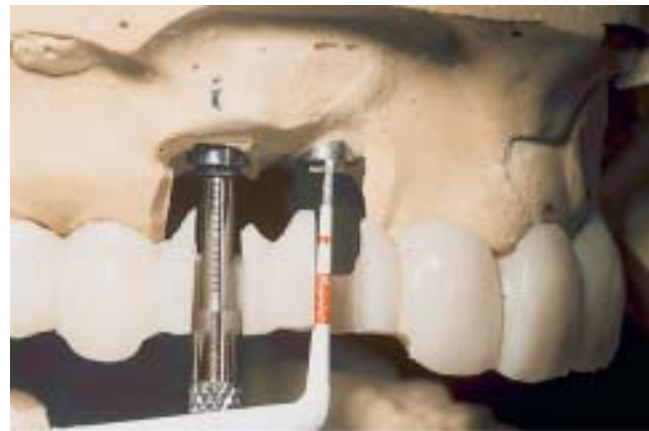R



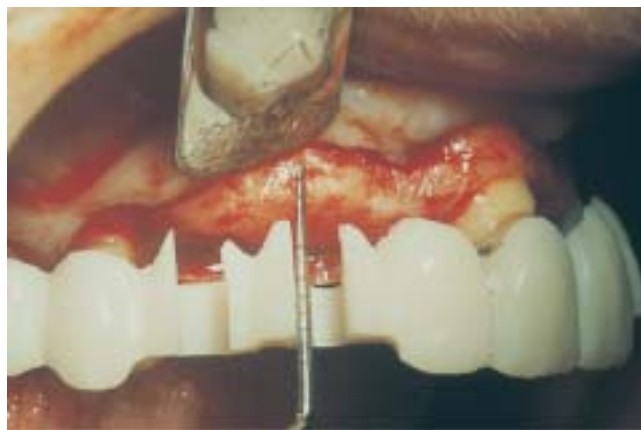S



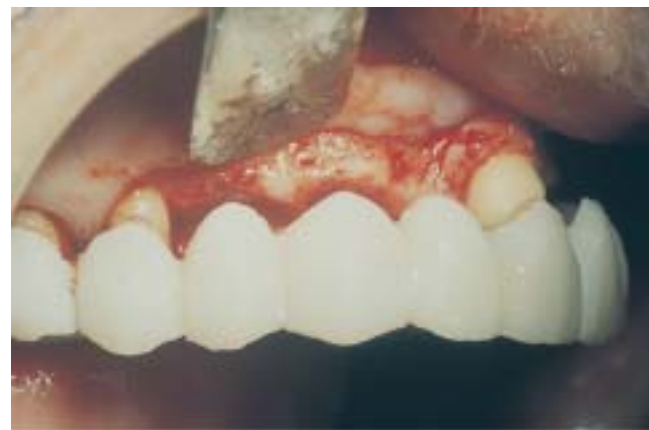T



U



V

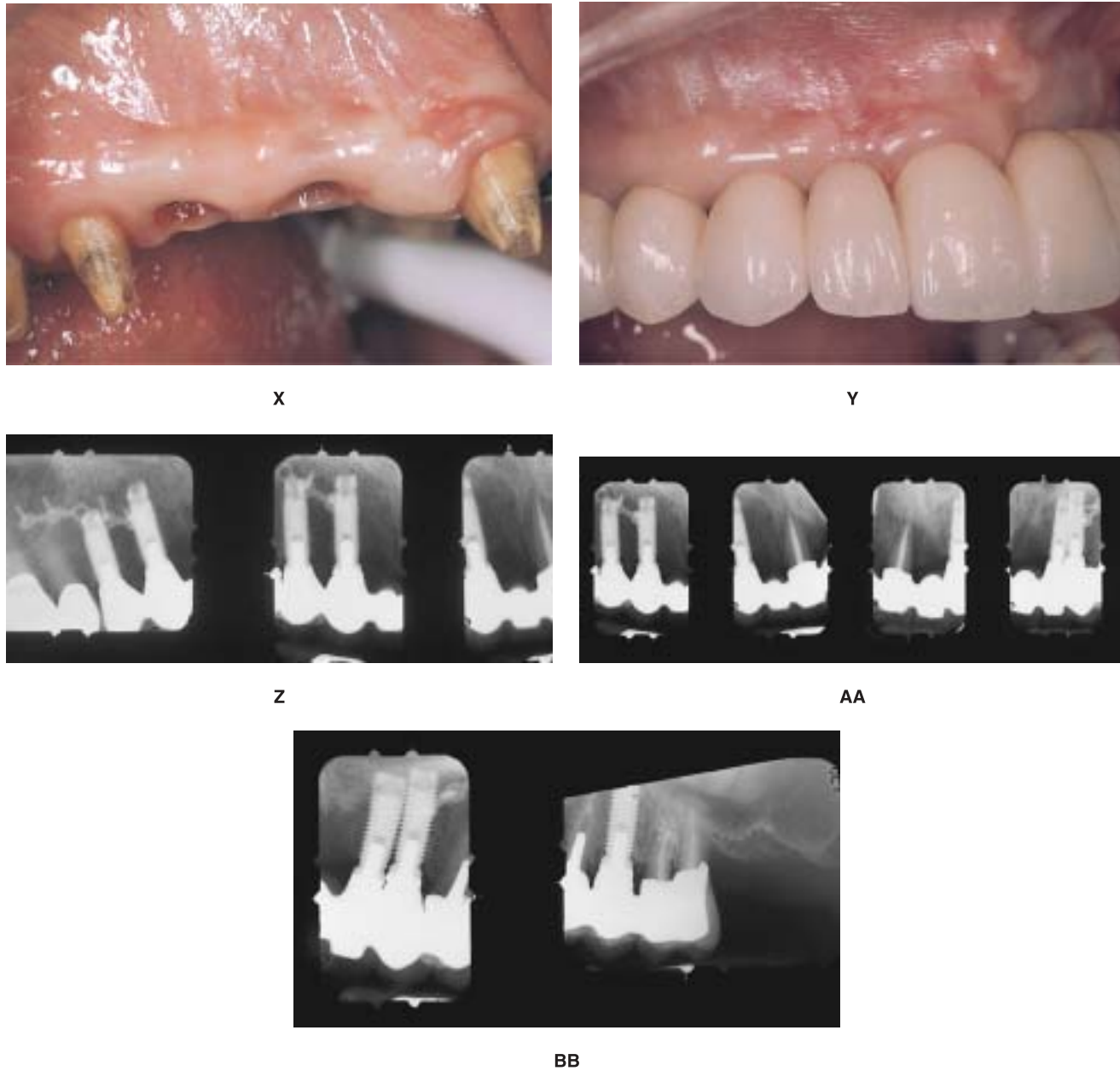


W

**Figure 27-11. cont'd** R, Postoperative healing of onlay graft sites. S, Panoramic radiographic view of the onlay graft sites. T, Interim provisional restoration. U, Vertical relation of endosseous implants to surgical template. V and W, Preparation of onlay graft site to install endosseous implants. First, the surgical template is installed. Measurements taken relative to the template will locate the implants vertically in the onlay-grafted bone, relative to the cemento-enamel junction of the adjacent teeth. Note the use of the second surgical template to define the rise and fall of the bony topography, relative to the vertical depth to which each implant is positioned. Implants installed to proper mesiodistal, buccopalatal, and vertical positions (performed by Dr. Garry Miller).

*Continued*





**Figure 27-11. cont'd** X, Soft tissue topography without demonstrating modest rise and fall to gingival topography. Y, Final ceramo-gold implant and tooth-supported restoration. Z-BB, Final maxillary radiographic images.

*Continued*

After the bony ridge has been reconstructed and the endosseous implants installed, a sufficient healing period must be observed to ensure a satisfactory “take.” Bone remodeling adjacent to implant fixtures occurs over a period of at least a year, leading to more mature bone (compact lamellar bone) within which the implant can better tolerate the forces of occlusion.<sup>91</sup>

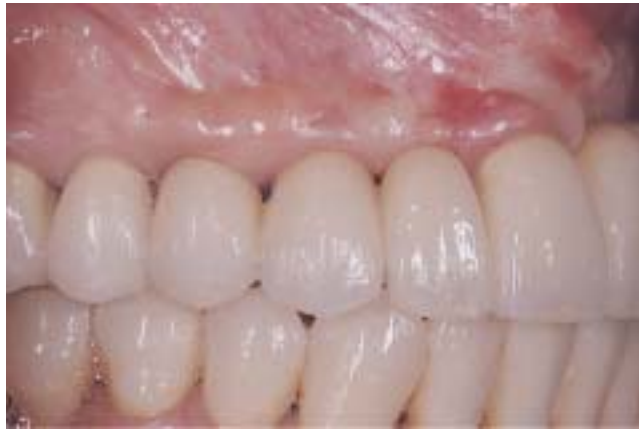The essential criteria for alveolar ridge reconstruction and successful implant placement are the following:

(1) appropriate quantity of horizontal and vertical bone and adequate quality of bone; (2) sufficient keratinized tissue overlying the bony crest; and (3) adequate distance between implants.<sup>8</sup>

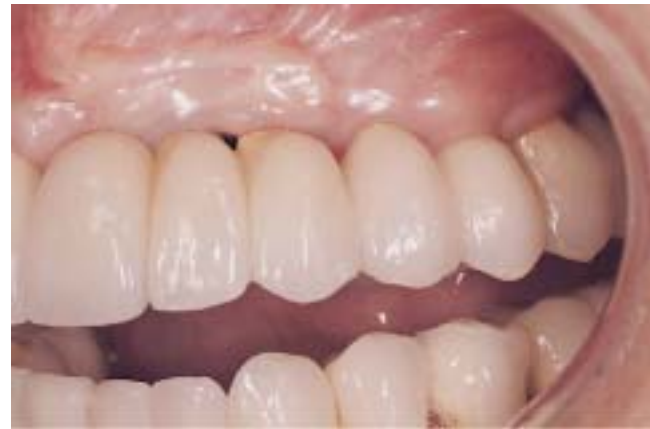#### **Transitional Implant-Assisted Restoration**

It is important to coordinate the schedules of the surgeon and the restorative dentist to begin the process of restoring the implants after an established healing period.

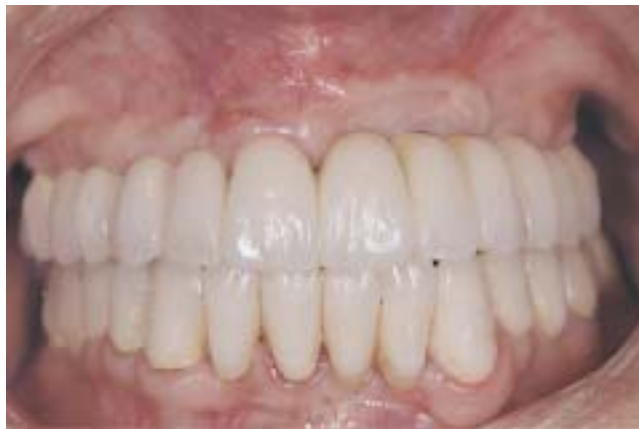



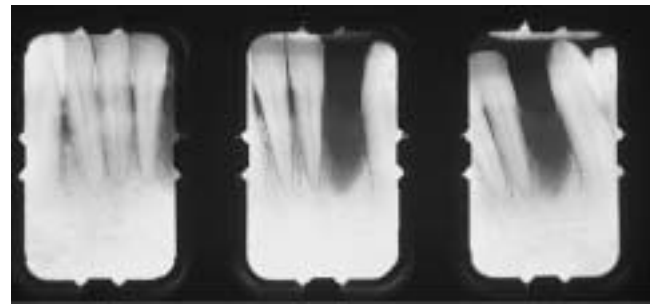
CC



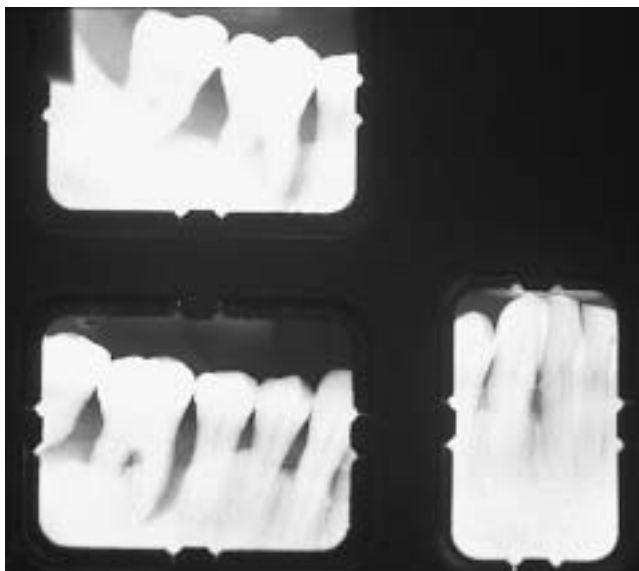
EE



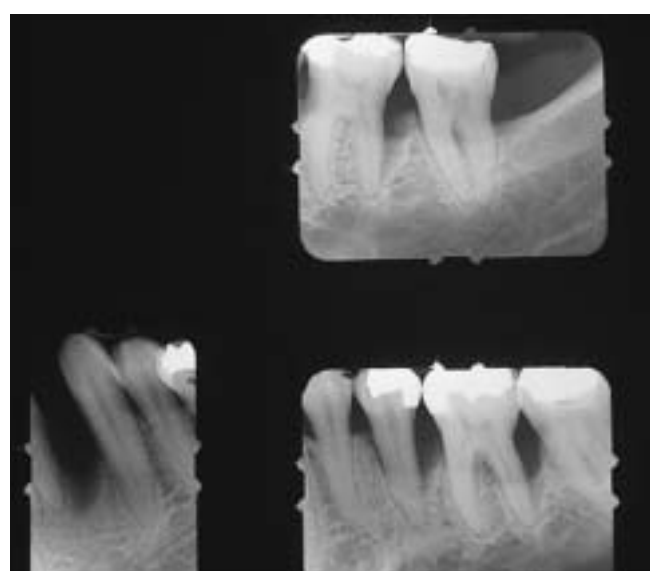
DD



GG



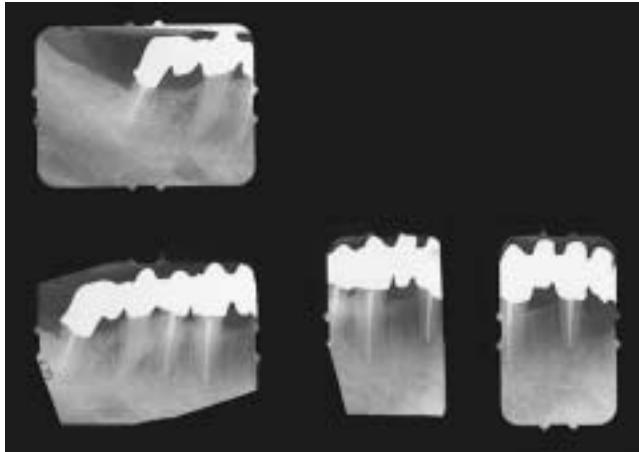
FF



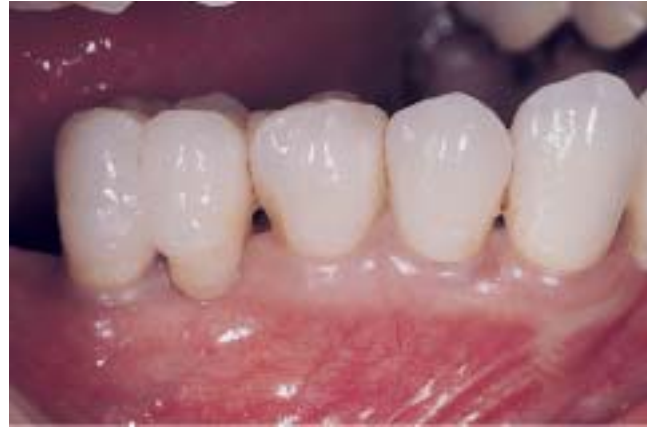HH

**Figure 27-11. cont'd CC-EE**, Final ceramo-gold restorations demonstrating reasonably normal soft tissue topography. The adjacent endosseous implants minimize the potential to preserve the height of the interproximal papilla (as described by Tarnow and colleagues<sup>8</sup>). **FF-HH**, Preoperative mandibular radiographs.

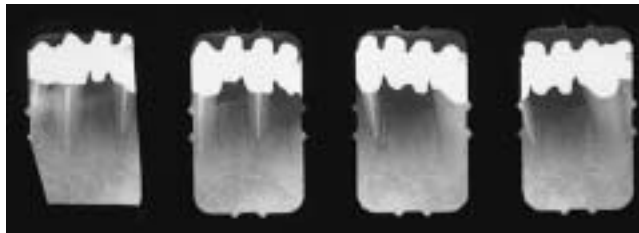
*Continued*



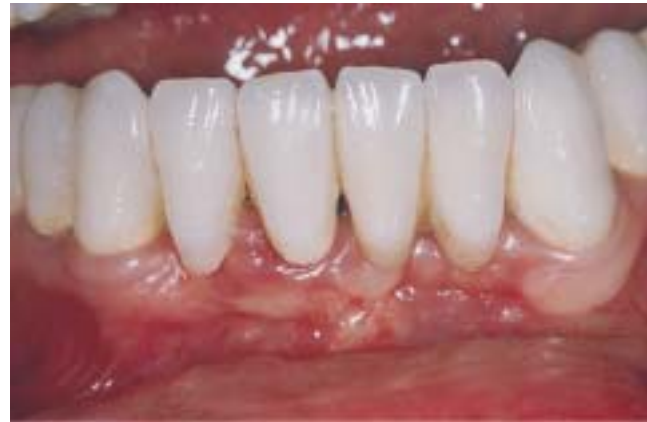II



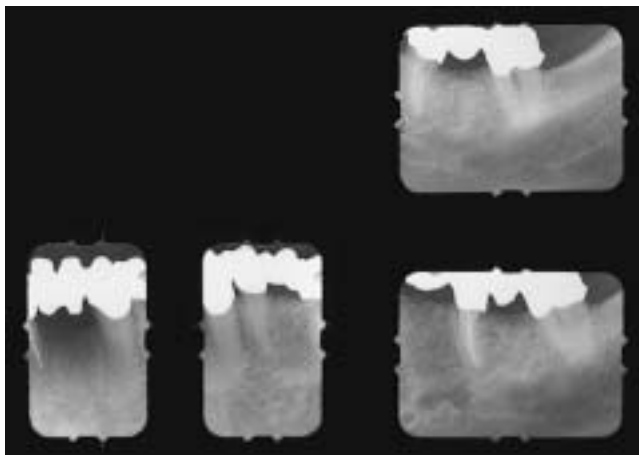
LL



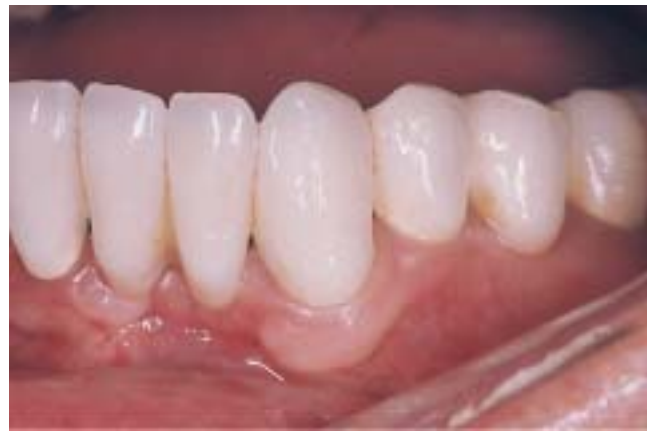JJ



MM

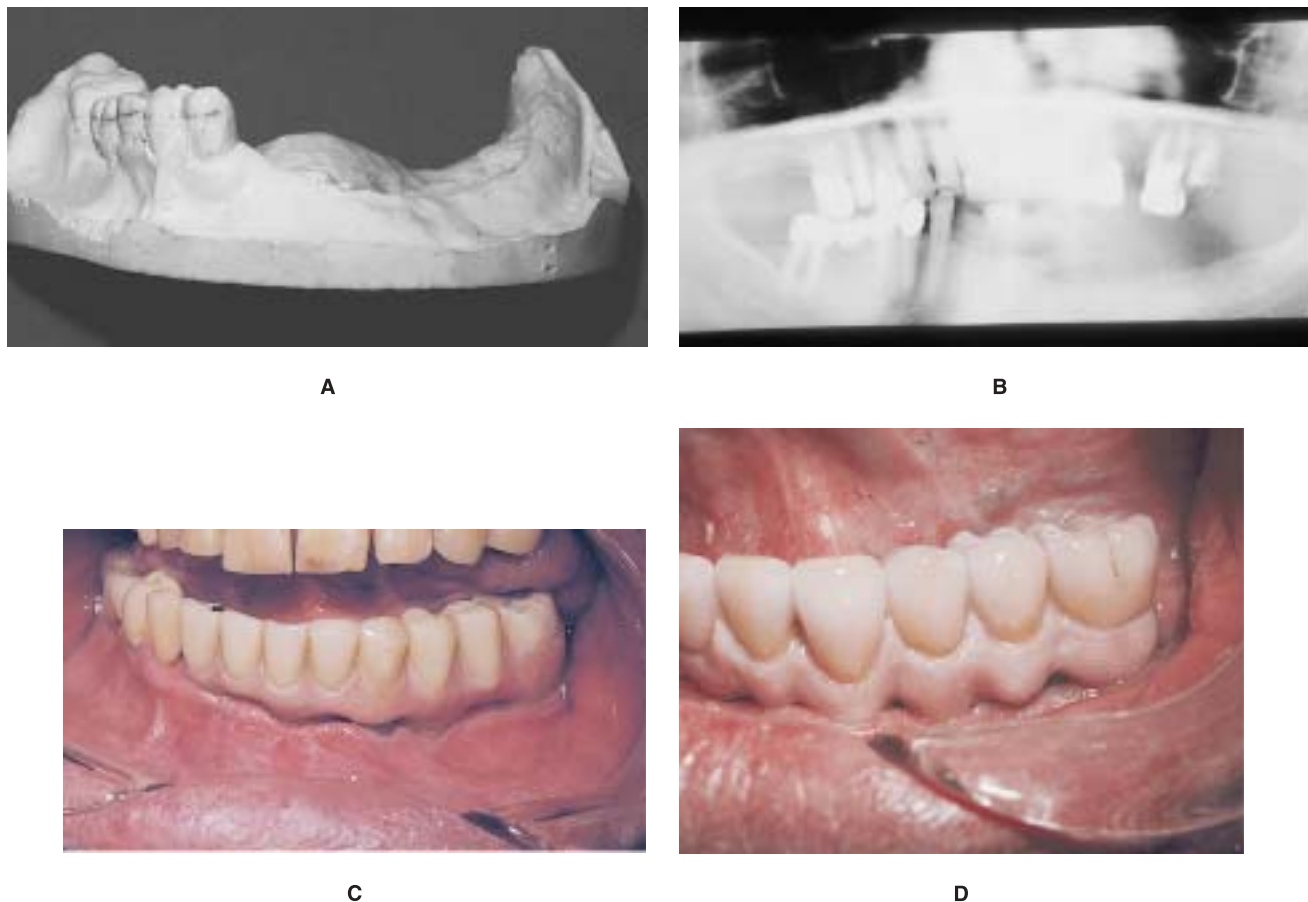


KK



NN

Figure 27-11. cont'd II-KK, Final ceramo-gold tooth-supported restorations: mandibular radiographs. LL-NN, Final ceramo-gold tooth-supported mandibular restoration with root resected molars and extraction of hopeless teeth.



**Figure 27-12.** **A**, Preoperative model view of residual ridge extending from former tooth site #17 through #26 inclusive—a result of the removal of a squamous cell carcinoma. **B**, Panoramic view of residual ridge extending from former tooth #17 through #26 inclusive. **C**, Provisional implant-supported restoration. **D**, Implant-supported ( $\times 5$ ), fixed, ceramo-gold restorations, replacing the anatomic crown, root, and gingiva—the Misch FPIII<sup>109</sup> classification for fixed implant prostheses (implant placement by Dr. Karl A. Rose).

The surgeon will perform a small gingival punch procedure to expose the head of the implant or a muco-periosteal flap procedure to reposition the gingival complex around the implants. A transepithelial healing component is then secured to the implant. After soft tissue maturation,<sup>8,92-95</sup> a high or low profile transepithelial abutment may be selected depending on the biologic dimension of tissues,<sup>96</sup> and a provisional restoration is fabricated to restore form and function. For “one-stage” implants, the restorative dentist can begin the provisional restoration at the appropriate scheduled time.

When multiple implants are exposed and angulation is a concern, it may be beneficial to take an impression that records the orientation of the fixture heads after early soft tissue healing. A new provisional restoration is then fabricated in the laboratory (Fig. 27-5), using temporary cylinders that are designed to mate directly with the implant body.<sup>97</sup>

Frequently at the second stage, the existing interim provisional prosthesis is modified by shortening the undersurface of the pontics to provide room for the healing components. Later these components are removed, abutments of proper height are screwed into position and temporary crown cylinders are seated, shortened to contact the opposing occlusion, and incorporated into the existing provisional restoration.

If there is any doubt as to the feasibility of accomplishing functional and esthetic alignment of the implant abutments, temporary crown cylinders are available from most implant manufacturers. They ensure an intimate fit to the titanium abutment or fixture head and allow the clinician to start developing the anticipated contours. Should the form require modification, the acrylic offers ample opportunity to make any modifications without jeopardizing the accuracy of the fit.

Chiche and colleagues<sup>98</sup> have pointed out that as a result of “surgical and anatomic limitations, implant

placement may not correspond to the initial expectation set at the presurgical phase, and over-contouring the final restoration could create aesthetic and functional liabilities." They continue their explanation, stating that "the path of emergence of the fastening screw through the prosthesis may compromise part of the facial or occlusal morphology, especially if it passes through a primary centric occlusal contact, an interproximal embrasure" or the facial veneer. "Even minor discrepancies between an implant and crown axis may result in eccentric screws, since such deviations are magnified at the level of the occlusion." Here the transitional prosthesis is invaluable in diagnosing these prosthetic limitations. With this early awareness, a plan can be better anticipated involving the use of angled abutments, custom-angled abutments, the fabrication of an auxiliary substructure, and the application of pink ceramic to facilitate the prosthetic result by the dental laboratory. Some have conjectured that the implant-assisted provisional restoration may provide a shock-dampening effect that may be beneficial during the first year of bone maturation adjacent to the implant fixtures.

At this stage, a radiographic and clinical evaluation of the stability of the implant fixtures is made. The compromised teeth that were retained to support the interim prosthesis are extracted at this time.<sup>52</sup> Some of the natural teeth may be removed in favor of additional implants or retained as indirect retainers in situations in which fewer implants are used in the overall support of the prosthesis. If a new transitional prosthesis has recently been fabricated, there may have been a change in the occlusal vertical dimension or the esthetic form, both of which would require further modification. In addition, it may be necessary to consider mucogingival treatment to enhance the complex of attached masticatory mucosa around selected teeth or implants.<sup>99</sup>

A transepithelial collar of minimal height, shallow sulcus depth, and a circumscribed border of bound-down keratinized tissue are essential for conventional plaque-control measures around implant crowns.

### Final Prosthetic Phase of Treatment

Now that the final prognoses for all teeth and implants have been established, the restorative dentist can use crown and bridge techniques to construct the final prosthesis. The dentist may proceed with final impressions of the natural teeth, relate them to the proper position of the implant fixtures or abutments, and fabricate a master model. To initiate the laboratory procedures, the case is carefully mounted on an appropriate articulator by means of a series of occlusal registrations.

On the master model, a soft tissue marginal profile should be fashioned around each natural tooth die and implant analogue to simulate the gingival condition in

the oral cavity. This allows for predictable abutment head selection in terms of proper height, angulation, and emergence profile. Technical choices are made concerning case design, case construction, the use of telescopic copings on retained natural teeth, or the use of precision "dovetail" slide attachments to interlock sections of teeth and implants, when indicated. When fixed implant-supported prostheses in combination with a removable partial denture are used, "stress-relieving" attachments may be considered.

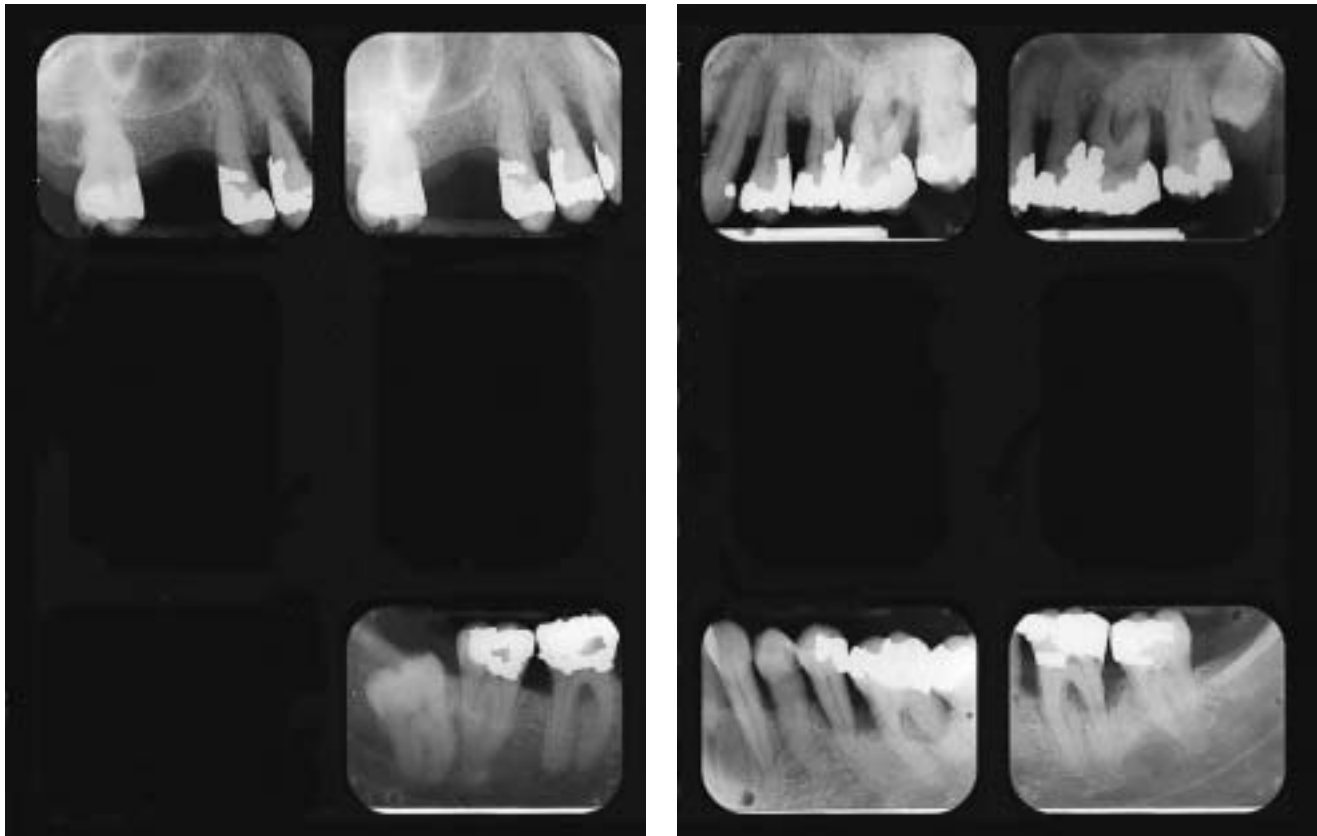
The primary substructure is fabricated and examined relative to the gingival margin placement; the fit of the copings is tested individually then collectively soldered, and the final ceramo-metal restoration is completed. Today it is possible for the computer to be used as a complementary or alternative technique to conventional impressions. Photogrammetry with digitized images, and laser/optical scanners can support computer-assisted design/computer-assisted manufacturing and computer-milling techniques in the fabrication of titanium-implant frameworks and ceramic and zirconium-oxide implant frameworks.<sup>100</sup> On delivery of the final prosthesis, a strong cement is used to secure the crowns on the remaining teeth. The fixture-assisted dental reconstruction is then seated with a temporary cement to create a hermetic seal at the interface of the abutment and superstructure. Retention and resistance to displacement may be enhanced by securing the prosthesis with set screws.<sup>101</sup> Using carefully machined/milled abutments, the practitioner may choose to cement the prosthesis in lieu of screw retention.<sup>102</sup>

### Long-Term Maintenance/Professional Care

The completed prosthesis and its supporting components (teeth and implants) are carefully monitored with a maintenance program, alternating visitations between the surgeon and the restorative dentist (Fig. 27-13). Any tissue changes or prosthetic problems can be detected early and addressed efficiently.<sup>35,103,104</sup> Periapical and panoramic radiographs are taken at appropriate intervals to ascertain any changes that may have taken place at the bone/implant interface and around natural teeth.

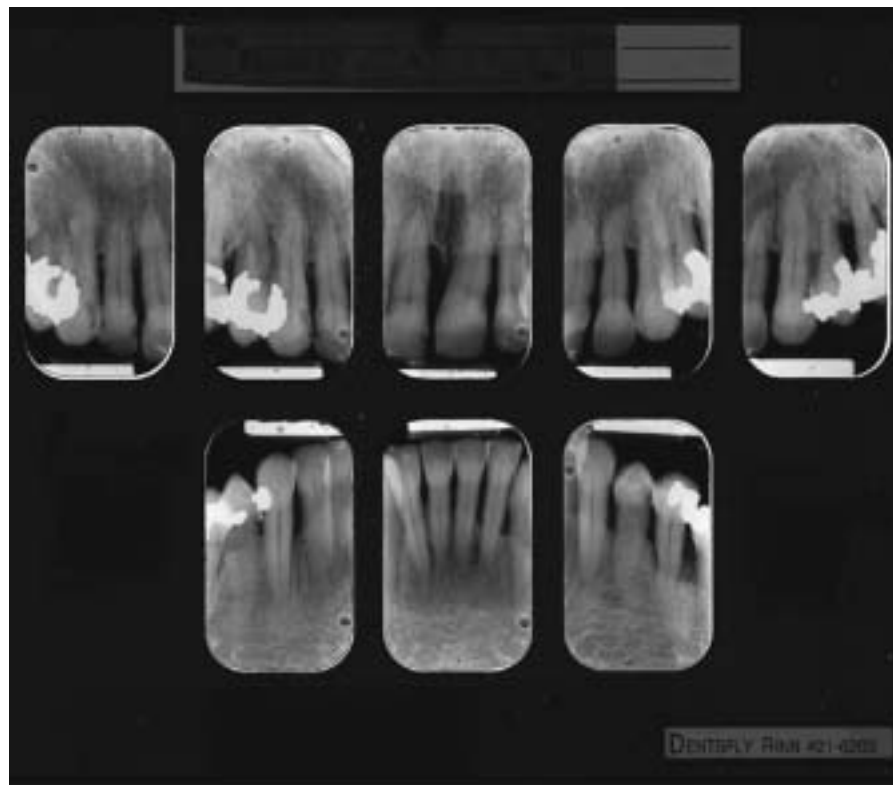
Mechanical failures (such as breakage of porcelain, solder joints, components, and implants) may occur long after the placement of the prosthesis, sometimes between 5 and 10 years.<sup>105</sup> According to Wiskott and colleagues,<sup>106</sup> fatigue failure is a "result of the development of microscopic cracks in areas of stress concentration." Continual loadings result in the cracks fusing to an ever-growing fissure that insidiously weakens the restoration. Eventually catastrophic failure results from a final loading cycle that exceeds the mechanical capacity of the remaining sound portion of the material. Based on the occlusal indicators, there may be great value in fitting the patient's dentition





A1

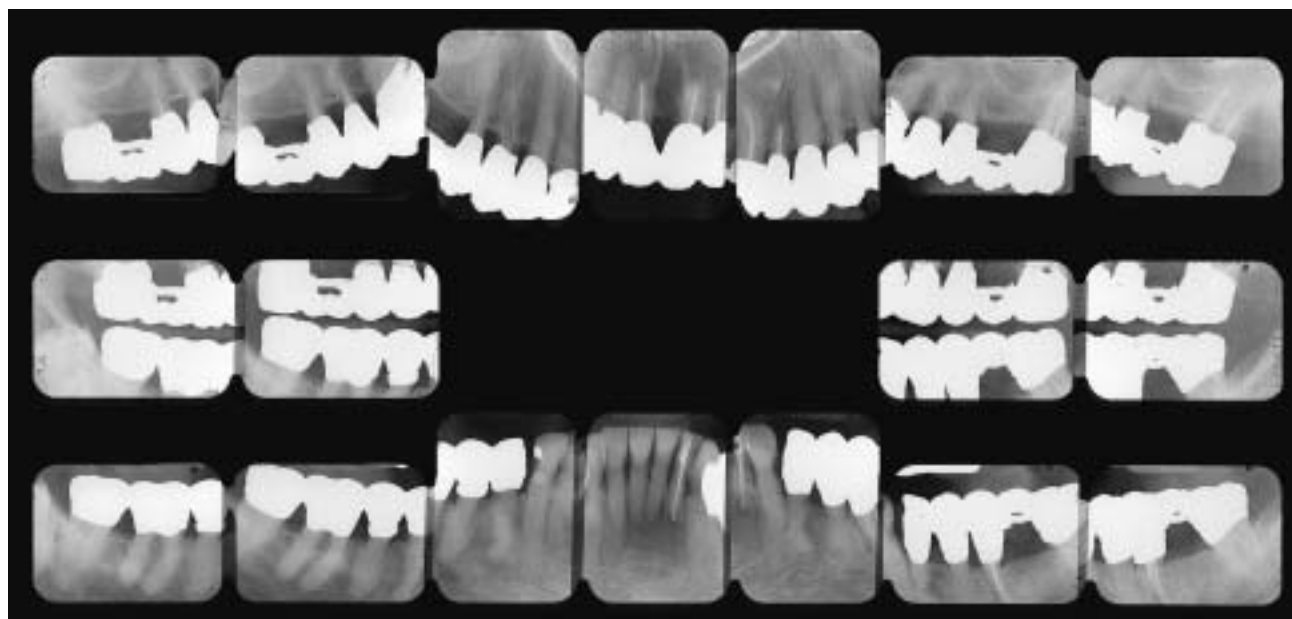A2



A3

**Figure 27-13. A,** Pretreatment full-mouth radiographic series (year 2/1967) demonstrating missing teeth, severe periodontitis with furcation invasions, and marked areas of alveolar bone destruction around many maxillary and mandibular teeth.

*Continued*



B

**Figure 27-13. cont'd B,** Posttreatment full-mouth radiographic series (year 9/1997) demonstrating 30 years of clinical and radiographic follow-up. Note the long-term success and maintenance of the supporting teeth of the fixed splinted periodontal prosthesis (periodontal prosthetic treatment performed by Dr. Jeffrey Ingber).

with an occlusal appliance as part of the long-term preservation of the prosthesis.

### CONCLUSION

The field of periodontal prosthesis has contributed much to our understanding of dental diseases and the methods of treating these problems. Periodontal prosthesis has truly been the hallmark of interdisciplinary care. Its future lies in all disciplines acting in concert to expand and enhance the accomplishments made during the last 50 years.

### ACKNOWLEDGMENTS

This chapter is dedicated to Dr. Morton Amsterdam, the father of Periodontal Prosthesis. Any errors in omission or commission are not his, but are attributable to us, the authors. Additional thanks go to Sylvie Ruppel-Bozilov for her technical assistance in the preparation of this manuscript.

The authors thank the Seattle Study Club and Dr. Michael Cohen specifically, for allowing us to update and reprint much of the article Starr, N.L., "Treatment Planning and Treatment Sequencing With and Without Endosseous Implants; A Comprehensive Therapeutic Approach to the Partially Edentulous Patient", Seattle Study Club Journal; 1995; 1:1, 21-34.

### REFERENCES

1. Amsterdam M: Periodontal prosthesis—twenty-five years in retrospect, *Alpha Omegan* 67:8-52, 1974.
2. Amsterdam M, Abrams L: Periodontal prosthesis. In Goldman HM, Cohen DW, editors: *Periodontal therapy*, St. Louis, 1973, CV Mosby Company, pp 977-1013.
3. Adell R, Lekholm U, Rocklen B, Branemark PJ: A 15-year study of osseointegrated implants in the treatment of the edentulous jaw, *Int J Oral Surg* 10:387-416, 1981.
4. Amsterdam M, Weisgold AS: Periodontal prosthesis: a 50-year perspective, *Alpha Omegan* 93:23-30, 2000.
5. Tarnow DP, Magner AW, Fletcher P: The effect of the distance from the contact point to the crest of bone on the presence or absence of the interproximal dental papilla, *J Periodontol* 63:935-996, 1992.
6. Choquet V, Hermans M, Adrianssens P et al: Clinical and radiographic evaluation of the papilla level adjacent to single-tooth dental implants. A retrospective study in the maxillary anterior region, *J Periodontol* 72:1364-1371, 2001.
7. Salama H, Salama M, Garber D, Adar P: The interproximal height of bone. A guidepost to predictable aesthetic strategies and soft tissue contours in anterior tooth replacement, *Pract Periodontics Aesthet Dent* 10:1131-1141, 1998.
8. Tarnow D, Cho SC, Wallace SS: The effect of inter-implant distance on the height of inter-implant bone crest, *J Periodontol* 4:546-549, 2000.

9. Garber D: The esthetic dental implant: letting the restoration be the guide, *J Am Dent Assoc* 126:319-325, 1995.
10. Kois JC: Predictable single tooth peri-implant esthetics: five diagnostic keys, *Compend Contin Educ Dent* 22:199-206, 2001.
11. Salama H, Salama M, Garber D et al: Developing optimal peri-implant papillae within the esthetic zone; guided soft tissue augmentation, *J Esthet Dent* 7:125-129, 1995.
12. Phillips K, Kois JC: Aesthetic peri-implant site development—the restorative connection, *Dent Clin North Am* 42:57-70, 1998.
13. Jansen C, Weisgold AS: Presurgical treatment planning for the anterior single tooth implant restoration, *Compend Contin Educ Dent* 16:746-761, 1995.
14. Weisgold AS, Arnoux J-P, Lu J: The single tooth anterior implant: a word of caution, part I, *J Esthet Dent* 9:225-233, 1998.
15. Ochsenbein C, Ross S: A concept of osseous surgery and its clinical applications. In Ward HL, Chas C, editors: *CDS. A periodontal point of view*. Springfield, Ill, 1973, Charles C. Thomas.
16. Weisgold AS: Contours of the full crown restoration, *Alpha Omegan* 10:77-89, 1977.
17. Olsson M, Lindhe J: Periodontal characteristics in individuals with varying forms of the upper central incisors, *J Clin Periodontol* 18:78-82, 1991.
18. Becker W, Ochsenbein C, Tibbetts L, Becker BE: Alveolar bone anatomic profiles as measured from dry skulls. Clinical ramifications, *J Clin Periodontol* 24:727-731, 1997.
19. Magne P, Douglas WH: Additive contour of porcelain veneers: a key element in enamel preservation, adhesion, and esthetics for aging dentition, *J Adhes Dent* 1(1):81-92, 1999.
20. Svanberg G, Lindhe J: Experimental tooth hypermobility in the dog: a methodological study, *Odontol Revy* 24:269-282, 1973.
21. Kantor M, Polson AM, Zander H: Alveolar bone regeneration after removal of inflammatory and traumatic factors, *J Periodontol* 47:687-695, 1976.
22. Lindhe J, Nyman S: The role of occlusion in periodontal disease and the biological rationale for splinting in treatment of periodontitis, *Oral Sci Rev* 10:11-43, 1977.
23. Starr NL: The distal extension case: an alternative restorative design for implant prosthetics, *Int J Periodontics Restorative Dent* 21:1, 61-67, 2001.
24. Lindhe J, Svanberg G: Influence of trauma from occlusion on progression of experimental periodontitis in the beagle dog, *J Clin Periodontol* 1:3-14, 1974.
25. Lindhe J, Svanberg G: Vascular reactions in the periodontal ligament incident to trauma from occlusion, *J Clin Periodontol* 1:58-69, 1974.
26. Lindhe J, Ericsson I: Influence of trauma from occlusion on reduced but healthy periodontal tissues in dogs, *J Clin Periodontol* 3:110-122, 1976.
27. Ericsson I, Lindhe J: Lack of effect of trauma from occlusion on the recurrence of experimental periodontitis, *J Clin Periodontol* 4:115-127, 1977.
28. Lindhe J, Nyman S: The role of occlusion in periodontal disease and the biological rationale for splinting in treatment of periodontitis, *Oral Sci Rev* 10:11-43, 1977.
29. Nyman S, Lindhe J, Ericsson I: The effect of progressive tooth mobility on destructive periodontitis in the dog, *J Clin Periodontol* 5:213-225, 1978.
30. Waerhaug J: The infrabony pocket and its relationship to trauma from occlusion and subgingival plaque, *J Periodontol* 50:355-365, 1979.
31. Ericsson I, Lindhe J: Effect of longstanding jiggling on experimental marginal periodontitis in the beagle dog, *J Clin Periodontol* 9:497-503, 1982.
32. Lindhe J, Ericsson I: Effect of elimination of the jiggling forces on periodontally exposed teeth in the dog, *J Periodontol* 53:562-567, 1982.
33. Philstom BL, Anderson KA, Aeppli D, Schaffer EM: Association between signs of trauma from occlusion and periodontitis, *J Periodontol* 57:1-6, 1986.
34. Rangert B, Jemt T, Jorneus L: Forces and moments on Branemark implants, *Int J Oral Maxillofac Implants* 4:241-247, 1989.
35. Starr NL: Treatment planning and treatment sequencing with and without endosseous implants: a comprehensive therapeutic approach to the partially edentulous patient, *Seattle Study Club Journal* 1:1, 21-34, 1995.
36. Israelson H, Plemons JM, Watkins P, Sony C: Barium-coated surgical stents and computer-assisted tomography in the preoperative assessment of dental implant patients, *Int J Periodontics Restorative Dent* 12:53-61, 1992.
37. Gurel G: Predictable, precise, and repeatable tooth preparation for porcelain laminate veneers, *Pract Proced Aesthet Dent* 15(1):17-24, 2003.
38. Marks MH: Tooth movement in periodontal therapy. In Goldman HM, Cohen DW, editors: *Periodontal therapy*, St. Louis, 1973, CV Mosby Company, pp 533-537.
39. Nyman S, Lindhe J, Karring T: Reattachment—new attachment. In Lindhe J, editor: *Textbook of clinical periodontology*, Copenhagen, 1989, Munksgaard, pp 450-476.
40. Lekholm U, Zarb GA, editors: *Tissue-integrated prostheses: osseointegration in clinical dentistry*. Chicago, 1985, Quintessence Publishing Company, pp 199-209.
41. Albrektsson T, Zarb GA, Worthington P, Eriksson AR: The long-term efficacy of currently used dental implants: a review and proposed criteria of success, *Int J Oral Maxillofac Implants* 1:11-25, 1986.
42. Zarb GA, Schmitt A: The longitudinal clinical effectiveness of osseointegrated dental implants. The Toronto Study. Part I: surgical results, *J Prosthet Dent* 62:451-457, 1989.
43. Zarb GA, Schmitt A: The longitudinal clinical effectiveness of osseointegrated dental implants. The Toronto

- Study. Part II: the prosthetic results, *J Prosthet Dent* 64:53-61, 1989.
44. Zarb GA, Schmitt A: The longitudinal clinical effectiveness of osseointegrated dental implants. The Toronto Study. Part III: problems and complications encountered, *J Prosthet Dent* 64:185-194, 1989.
  45. Friberg B, Jemt T, Lekholm U: Early failures in 4,641 consecutively placed Branemark dental implants: a study from stage I surgery to the connection of the completed prostheses, *Int J Oral Maxillofac Implants* 6:142-146, 1991.
  46. Lekholm U, Adell R, Lindhe J et al: Marginal tissue reactions at osseointegrated titanium fixtures. (II) A cross-sectional retrospective study, *Int J Oral Maxillofac Surg* 15:53-61, 1986.
  47. Nevins M, Mellonig JT: Enhancement of the damaged edentulous ridge to receive dental implants: a combination of allograft and the Gore-Tex membrane, *Int J Periodontics Restorative Dent* 12:97-111, 1992.
  48. Misch CM, Misch CE, Resnick RR, Ismail YH: Reconstruction of maxillary alveolar defects with mandibular symphysis grafts for dental implants: a preliminary procedural report, *Int J Oral Maxillofac Implants* 3:360-366, 1992.
  49. Hirsch JM, Ericsson I: Maxillary sinus augmentation using mandibular bone grafts and simultaneous installation of implants. A surgical technique, *Clin Oral Implants Res* 2:91-96, 1991.
  50. Hurzeler MB, Kirsch A, Ackermann K-L, Quinones CR: Reconstruction of the severely resorbed maxilla with dental implants in the augmented maxillary sinus: a 5-year clinical investigation, *Int J Oral Maxillofac Implants* 11:466-475, 1996.
  51. Amsterdam M, Fox I: Provisional splinting—principles and techniques, *Dent Clin North Am* 3:73, 1959.
  52. Langer B, Sullivan DY: Osseointegration: its impact on the interrelationship of periodontics and restorative dentistry. Part III, *Int J Periodontics Restorative Dent* 4:241-261, 1989.
  53. Ericsson I, Lekholm U, Branemark PI et al: A clinical evaluation of fixed bridge restorations supported by the combination of teeth and osseointegrated implants, *J Clin Periodontol* 13:307-312, 1986.
  54. Ericsson I, Glantz PO, Branemark PI: Use of implants in restorative therapy in patients with reduced periodontal tissue support, *Quintessence Int* 19:801-807, 1988.
  55. Van Steenberghe D: A retrospective multicenter evaluation of the survival rate of osseointegrated fixtures supporting fixed partial prostheses in the treatment of partial edentulism, *J Prosthet Dent* 61:217-223, 1989.
  56. Van Steenberghe D, Lekholm U, Bolender C et al: The applicability of osseointegrated oral implants in the rehabilitation of partial edentulism: a prospective multicenter study of 558 fixtures, *Int J Oral Maxillofac Implants* 5:272-281, 1990.
  57. Jemt T, Lekholm U, Adell R: Osseointegrated implants in the treatment of partially edentulous patients: a preliminary study on 876 consecutively placed fixtures, *Int J Oral Maxillofac Implants* 4:211-217, 1989.
  58. Klinge B: Implants in relation to natural teeth, *J Clin Periodontol* 18:482-487, 1991.
  59. Astrand P, Borg K, Gunne J, Olsson M: Combination of natural teeth and osseointegrated implants as prosthesis abutments: a 2-year longitudinal study, *Int J Oral Maxillofac Implants* 3:305-312, 1991.
  60. Gunne J, Astrand P, Ahlen K et al: Implants in partially edentulous patients: a longitudinal study of bridges supported by both implants and natural teeth, *Clin Oral Implants Res* 2:49-56, 1992.
  61. Pylant T, Triplett RG, Brunsvold MA: A retrospective evaluation of endosseous titanium implants in the partially edentulous patient, *Int J Oral Maxillofac Implants* 7:195-202, 1992.
  62. Buser D, Bragger U, Lang NP, Nyman S: Regeneration and enlargement of jaw bone using guided tissue regeneration, *Clin Oral Implants Res* 1:22-32, 1990.
  63. Jovanovic SA, Nevins M: Bone-formation utilizing titanium-reinforced barrier membranes, *Int J Periodontics Restorative Dent* 15:1, 1995.
  64. Schluger S: Osseous resection—a basic principle in periodontal surgery, *Oral Surg Oral Med Oral Pathol* 2:316, 1949.
  65. Ochsenbein C: Osseous resection in periodontal therapy, *J Periodontol* 29:15, 1958.
  66. Friedman N: Periodontal osseous surgery, osteoplasty, osteoectomy, *J Periodontol* 26:257, 1955.
  67. Salama H, Salama M: The role of orthodontic extrusive remodeling in the enhancement of soft and hard tissue profiles prior to implant placement: a systemic approach to the management of extraction site defects, *Int J Periodontics Restorative Dent* 13:312-333, 1993.
  68. Ingber JS: Forced eruption, I. A method of treating isolated one and two wall infrabony osseous defects—rationale and case report, *J Periodontol* 45:199-206, 1974.
  69. Ingber JS: Forced eruption, II. A method of treating isolated one and two wall infrabony osseous defects—rationale and case report, *J Periodontol* 47:203-216, 1976.
  70. Schnitman P, Wohrle P, Rubenstein J: Immediate fixed interim prosthesis supported by two stage threaded implants: methodology and results, *J Oral Implants* 16:96-105, 1990.
  71. Wong KM, Youdelis RA, Heindl H: Aesthetic tooth replacement using osseointegrated implants: pontics and immediate implant site development, *Pract Proced Aesthet Dent* 15:45-47, 2003.
  72. Proussaefs P: Histologic evaluation of an immediately loaded titanium provisional implant retrieved after functioning for 18 months: a clinical report, *J Prosthet Dent* 89:331-334, 2003.



73. Froum S, Emtiaz S, Bloom M et al: The use of transitional implants for immediate fixed temporary prosthesis in cases of implant restorations, *Pract Periodontics Aesthet Dent* 10:737-746, 1998.
74. Bohsali K, Simon H, Kan J, Redd M: Modular transitional implants to support the interim maxillary overdenture, *Compend Contin Educ Dent* 20:975-978, 980, 982-983, 1999.
75. Zubery Y, Bichacho N, Moses O, Tal H: Immediate loading of Modular transitional implants: a histologic and histomorphometric study in dogs, *Int J Periodontics Restorative Dent* 19:343-353, 1999.
76. Zitman N, Marinello G: Treatment plan for restoring the edentulous maxilla with implant-supported restorations: removable overdenture versus fixed partial denture design, *J Prosthet Dent* 82:188-196, 1999.
77. Starr NL, Miller GM: Implant placement in the vertically enhanced ridge, *Compend Contin Educ Dent* 22:13-22.
78. Sarment DP, Al-Shammari K, Kazor CE: Stereolithographic surgical templates for placement of dental implants in complex cases, *Int J Periodontics Restorative Dent* 23:287-295, 2003.
79. Langer B: Spontaneous in situ gingival augmentation, *Int J Periodontics Restorative Dent* 14:525-535, 1994.
80. Lazzara RJ: Immediate implant placement into extraction sites: surgical and restorative advantages, *Int J Periodontics Restorative Dent* 9:333-343, 1989.
81. Shanaman RH: The use of guided tissue regeneration to facilitate ideal prosthetic placement of implants, *Int J Periodontics Restorative Dent* 12:257-265, 1992.
82. Simion M, Trisi P, Piattelli A: Vertical ridge augmentation using a membrane technique associated with osseointegrated implants, *Int J Periodontics Restorative Dent* 14:496-511, 1994.
83. Buser D, Dula K, Hirt HP et al: Localized ridge augmentation using guided bone regeneration. In Buser D, Dahlin C, Schenk RK, editors: *Guided bone regeneration in implant dentistry*, Chicago, 1994. Quintessence, pp 189-233.
84. Froum SJ, Tarnow DP, Wallace SS et al: Sinus floor elevation using anorganic bovine bone matrix (Osteograf/N) with and without autogenous bone: a clinical, histologic, radiographic, and histomorphometric analysis—Part 2 of an ongoing prospective study, *Int J Periodontics Restorative Dent* 18:528-543, 1998.
85. Collins TA, Brown GK, Johnson N et al: Team management of atrophic edentulism with autogenous inlay, veneer, and split grafts and endosseous implants: case reports, *Quintessence Int* 26:79-93, 1995.
86. Keller EE, Tolman DE, Eckert S: Surgical-prosthetic reconstruction of advanced maxillary bone compromise with autogenous onlay block bone grafts and osseointegrated endosseous implants: a 12-year study of 32 consecutive patients, *Int J Oral Maxillofac Implants* 14:197-209, 1999.
87. Keller EE, Van Roekel NB, Desjardins RP et al: Prosthetic-surgical reconstruction of the severely resorbed maxilla with iliac bone grafting and tissue-integrated prostheses, *Int J Oral Maxillofac Implants* 3:155-165, 1987.
88. Chin M, Toth BA: Distraction osteogenesis in maxillofacial surgery using internal devices: review of five cases, *J Oral Maxillofac Surg* 54:45-53, 1996.
89. Siebert JS: Reconstruction of deformed, partially edentulous ridges, using full thickness onlay grafts. Part I. Technique and wound healing, *Compend Contin Educ Dent* 4:437-453, 1983.
90. Seibert JS, Louis JV: Soft-tissue ridge augmentation utilizing a combination onlay-interpositional graft procedure: a case report, *Int J Periodontics Restorative Dent* 16:310-321, 1996.
91. Roberts WE, Turley PK, Brezniak N, Fielder PJ: Implants: bone physiology and metabolism, *CDA J* 15:54-61, 1987.
92. Bengazi F, Wennstrom JL, Lekholm U: Recession of the soft tissue margin at oral implants. A 2-year longitudinal prospective study, *Clin Oral Implant Res* 7:303-310, 1996.
93. Small PN, Tarnow DP: Gingival recession around implants: a 1-year longitudinal prospective study, *Int J Oral Maxillofac Implants* 15:527-532, 2000.
94. Grunder U: Stability of the mucosal topography around single-tooth implants and adjacent teeth: 1-year results, *Int J Periodontics Restorative Dent* 20:11-17, 2000.
95. Small P-N, Tarnow DP, Cho S-C: Gingival recession around wide-diameter versus standard-diameter implants: a 3- to 5-year longitudinal prospective study, *Pract Periodontics Aesthet Dent* 13:143-146, 2001.
96. Berglundh T, Lindhe J: Dimension of the peri-implant mucosa. Biological width revisited, *J Clin Periodontol* 23:971-973, 1996.
97. Binon P: Provisionalization in implant prosthodontics for partially edentulous arch, *Dent Implantol Update* 6(8):57-61, 1995.
98. Chiche G, Weaver C, Pinault A, Elliot R: Auxiliary substructure for screw-retained prostheses, *Int J Prosthodont* 5:407-412, 1989.
99. Krekeler G, Schilli W, Diemer J: Should the exit of the artificial abutment tooth be positioned in the region of the attached gingiva? *Int J Oral Surg* 14:504-508, 1985.
100. Lang LA, Hoffensburger M, Wang R-F et al: The universal acceptance of a CAD/CAM created abutment by six implant systems. University of Michigan on line: Available at [www.umich.edu/~nbumictr/](http://www.umich.edu/~nbumictr/)
101. Rangert B, Gunne J, Sullivan DY: Mechanical aspects of a Branemark implant connected to a natural tooth: an in vitro study, *Int J Oral Maxillofac Implants* 6:177-186, 1991.
102. Hebel K, Gajjar R: Cement-retained versus screw-retained implant restorations: achieving optimal occlusion and esthetics in implant dentistry, *J Prosthet Dent* 77:28-35, 1997.

103. Van Steenberghe D: Periodontal aspects of osseointegrated oral implants ad modum Branemark, *Dent Clin North Am* 32:355-370, 1988.
104. Lekholm U, Ericsson I, Adell R, Slots J: The condition of soft tissues at tooth and fixture abutments supporting fixed bridges: a microbiological and histological study, *J Clin Periodontol* 13:558-562, 1986.
105. Baumgarten H, Chiche G: Diagnosis and evaluation of complications and failures associated with osseointegrated implants, *Compend Contin Educ Dent* 16:814-823, 1995.
106. Wiskott H, Nicholls J, Belser U: Stress fatigue: basic principles and prosthodontics implications, *Int J Prosthet* 8:105-116, 1995.
107. Armitage GC: Development of a classification system of periodontal disease and conditions, *Ann Periodontol* 4:1-6, 1999.
108. Pinault A, Chiche GJ: *Esthetics of anterior fixed prosthodontics*. Carol Stream, Ill, 1994, Quintessence Publishing.
109. Misch C: *Contemporary implant dentistry*. St. Louis, 1999, Mosby.